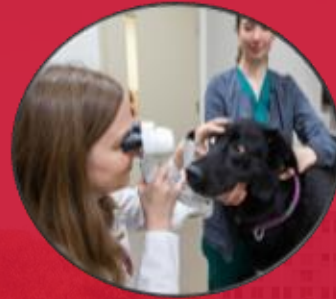

Ocular Emergencies



Jesus Diaz Bujan, BSAVA PgVertSA Opthal, MVetMed, Diplomate ECVO
Clinical Assistant Professor - Veterinary Ophthalmology

Ocular emergencies

- **Ophthalmic examination**
 - **Instruments and tests**
 - **Schirmer tear test (STT-1)**
 - **Tonovet**
 - **Fluorescein test**
- **Common ocular emergencies**
 - ~~Corneal foreign body~~
 - ~~Corneal ulceration~~
 - Acute glaucoma
 - Uveitis
 - Lens luxation
 - Sudden blindness
 - Retrobulbar abscess/cellulitis
 - Globe proptosis

Ophthalmic examination

- In a logical and systematic manner

Veterinary Ophthalmology,
Kirk N. Gelatt 2 Volume Set, 6th
Edition

- History: signalment, primary complaint, concurrent disease, and treatment
- Examination in ambient lighting
 - Distance examination
 - Observation of animal's demeanor and movement within its environment
 - Symmetry, ocular discharge
 - Globe (position, size, movement)
 - "Hands-on" examination
 - Neuro-ophthalmic testing: menace response, dazzle reflex, PLR, corneal reflex, VOR
 - Tear tests, corneal esthesiometry
 - Close examination of adnexa and globe
- Examination after topical anesthesia
 - Tonometry
 - Gonioscopy
 - Posterior TEL
- Mydriasis
 - Anterior segment after pupil dilation (lens)
 - Posterior segment after pupil dilation (vitreous humor and funduscopy)
- Additional diagnostic tests: corneoconjunctival culture and cytology, ophthalmic dyes, nasolacrimal flush, conjunctival biopsy, aqueous and vitreous paracentesis, imaging modalities, photography, ERG

Ophthalmic examination

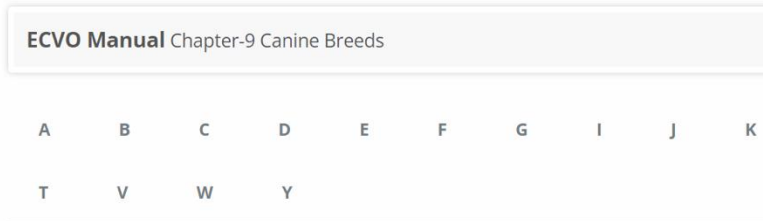
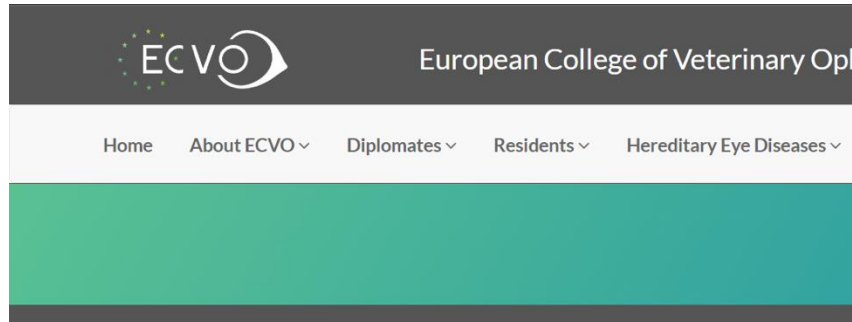
- **History**
 - **Signalment** (breed, age..)
 - **Primary complaint** (blepharospasm, ocular discharge, photophobia, etc)
 - **Concurrent disease** (diabetes, hypothyroidism, etc)
 - **Treatment** (topical ab, NSAIDs, etc)



<https://dthemspet.com/blog/doggie-doorbell-lets-your-dog-tell-you-they-need-to-go/>

Ophthalmic examination

<https://www.ecvo.eu/hereditary-eye-diseases/ecv>



Ocular disorders known or presumed to be inherited (published)

	Diagnosis	Description and comments specific to the breed	Inheritance	Gene/ marker test	References
A	Entropion/Macroblepharon	Medial lower entropion associated with macroblepharon	Polygenic suspected	NO	1, 2
B	Distichiasis	Corneal ulcers possible	Autosomal dominant with incomplete penetrance suspected	NO	1,2
C	Trichiasis	Nasal fold and caruncula	Unknown	NO	1,3
D	Exposure keratopathy	Lagophthalmia, corneal ulcers possible	Polygenic suspected	NO	1,3

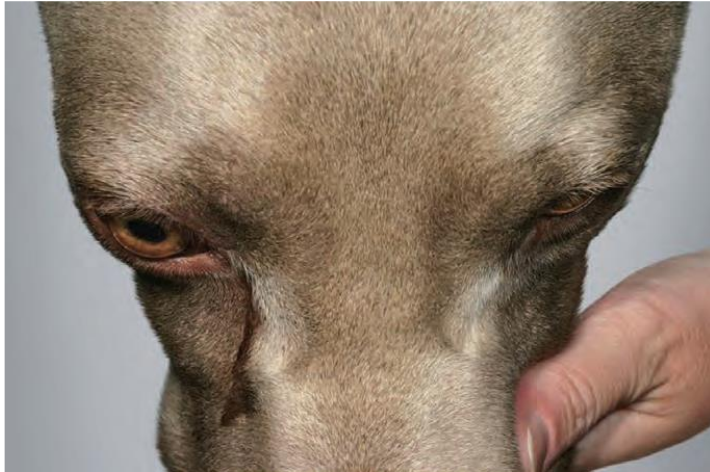Ophthalmic examination

- Distance examination
 - Observation of animal's demeanor and movement within its environment
 - Symmetry, ocular discharge
 - Globe (position, size, movement)
 - Pupil size
 - Tapetal reflection

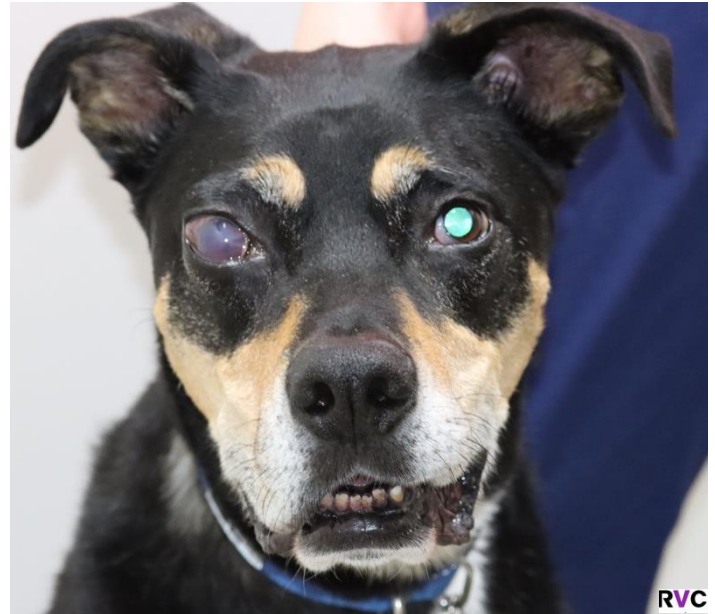

Ophthalmic examination

- Exophthalmos vs buphthalmia?

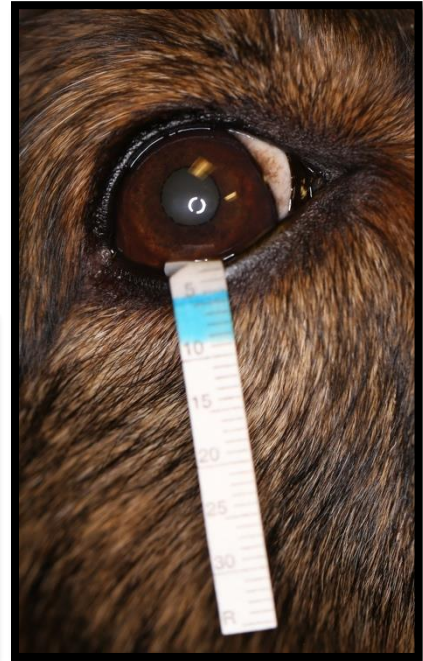
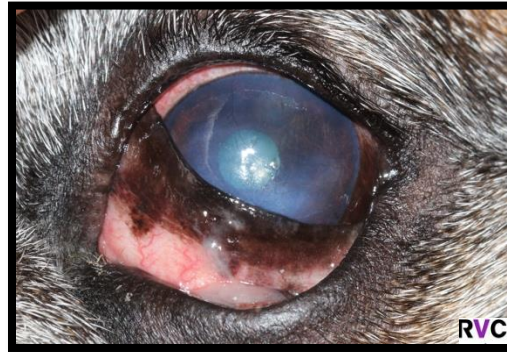
Veterinary Ophthalmology, Kirk N. Gelatt 2 Volume Set, 6th Edition



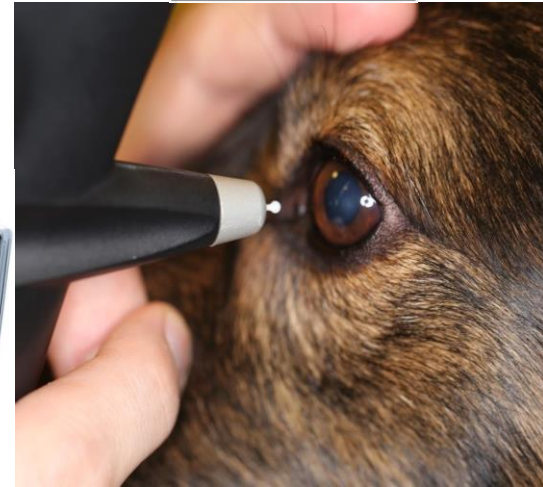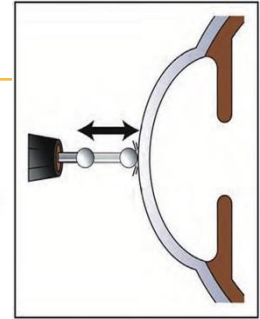
Ophthalmic examination

- “Hands-on” examination
 - 1st Schirmer tear test (normal range 15-25 mm/min)
(keratoconjunctivitis sicca)
 - **NOT – if there is suspicion of a perforated eye or very deep ulcer**



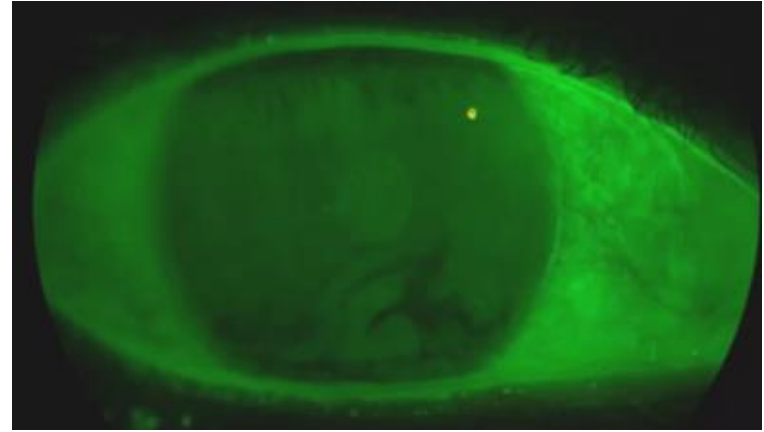
Ophthalmic examination

- Intraocular pressure (15-25mmHg)
 - **Always before the application of mydriatics!!!**
 - No pressure in the eyelids or globe
 - No pressure on the jugular veins (check collar)
 - Probe-to-cornea
 - Perpendicular
 - Distance 3–5 mm



Ophthalmic examination

- **Topical fluorescein sodium**
 - Ultraviolet or blue light
 - Detection of **corneal ulceration**
 - Aqueous humor leakage (**Seidel test**)
 - **Qualitative tear film abnormalities** (tear film breakup time)
 - To assess the physiological **flow of the nasolacrimal system (Jones test)**

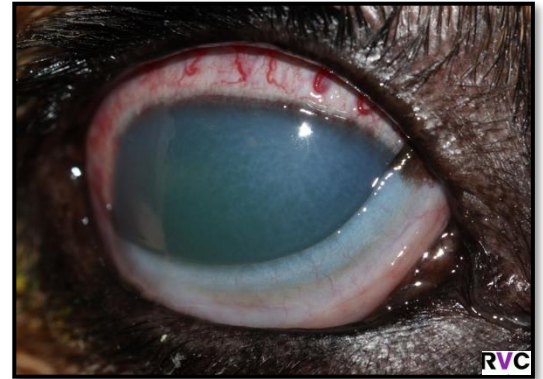


Ocular emergencies

- Ophthalmic examination
 - Instruments and tests
 - Schirmer tear test (STT-1)
 - Tonovet
 - Fluorescein test
- Common ocular emergencies
 - Acute glaucoma
 - Uveitis
 - Lens luxation
 - Sudden blindness
 - Retrobulbar abscess/cellulitis
 - Globe proptosis

Common ocular emergencies

- **Acute glaucoma**
- **Clinical signs:**
 - High intraocular pressure (IOP \geq 50mmHg can lead to blindness long-term!)
 - Blepharospasm, episcleral congestion, perilimbal corneal neovascularisation
 - **Blindness** (no menace)
 - **Fix dilated pupil**
 - **Diffuse corneal edema** (not always in cats)
 - Aqueous humor flare
 - Buphthalmia (chronic)



Common ocular emergencies

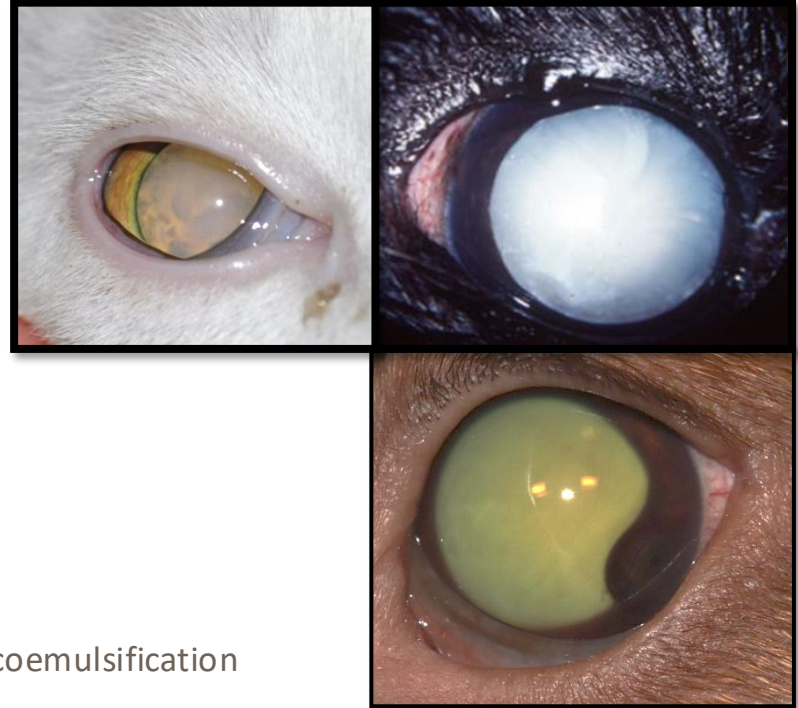- **Acute glaucoma**

- **Primary:**

- Open angle (POAG)
 - Angle closed (PACG)

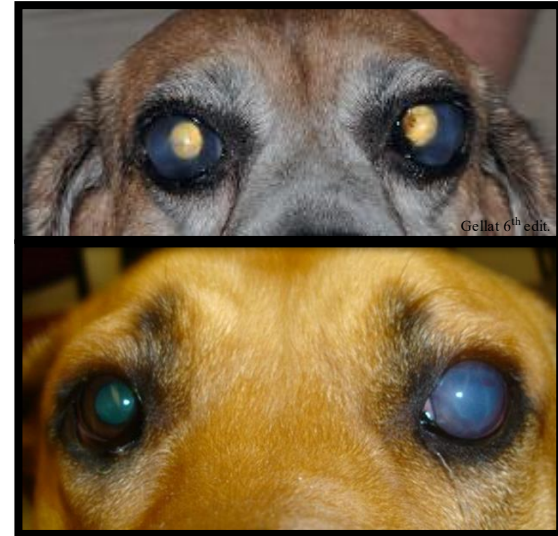- **Secondary:**

- Lens luxation
 - Chronic uveitis
 - Ocular trauma
 - Neoplasia
 - Secondary to intraocular surgery such as phacoemulsification



Classifications of Glaucoma: Primary

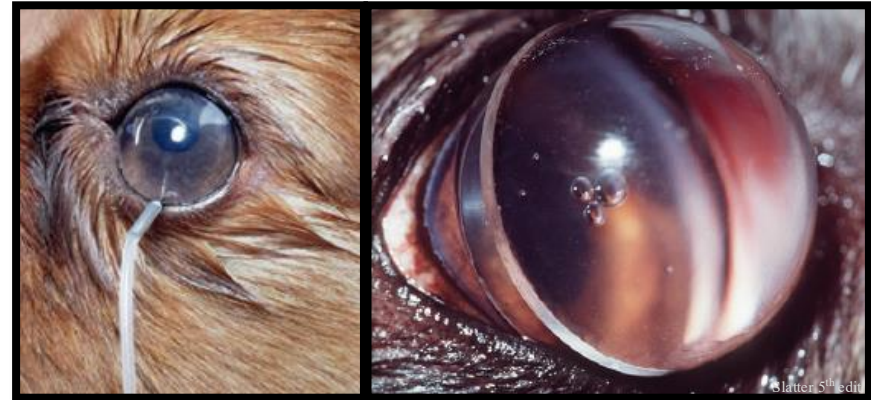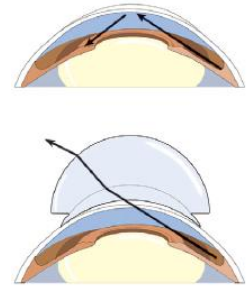
- **Open angle (POAG)**
 - Bilateral, slowly progressive
 - Breed predisposition: Beagles, Basset Hound, Shar Pei, etc.
- **Closed angle (PCAG) = Pectinate ligament dysplasia**
 - Most common in dogs!
 - Average age of onset: 6-8 years
 - Initially unilateral, but progresses to bilateral (\approx 8 months)
 - Breed predisposition: Basset hound, Cocker spaniel (American/English), Shar Pei, Shiba Inu, etc.



Diagnosis of primary glaucoma

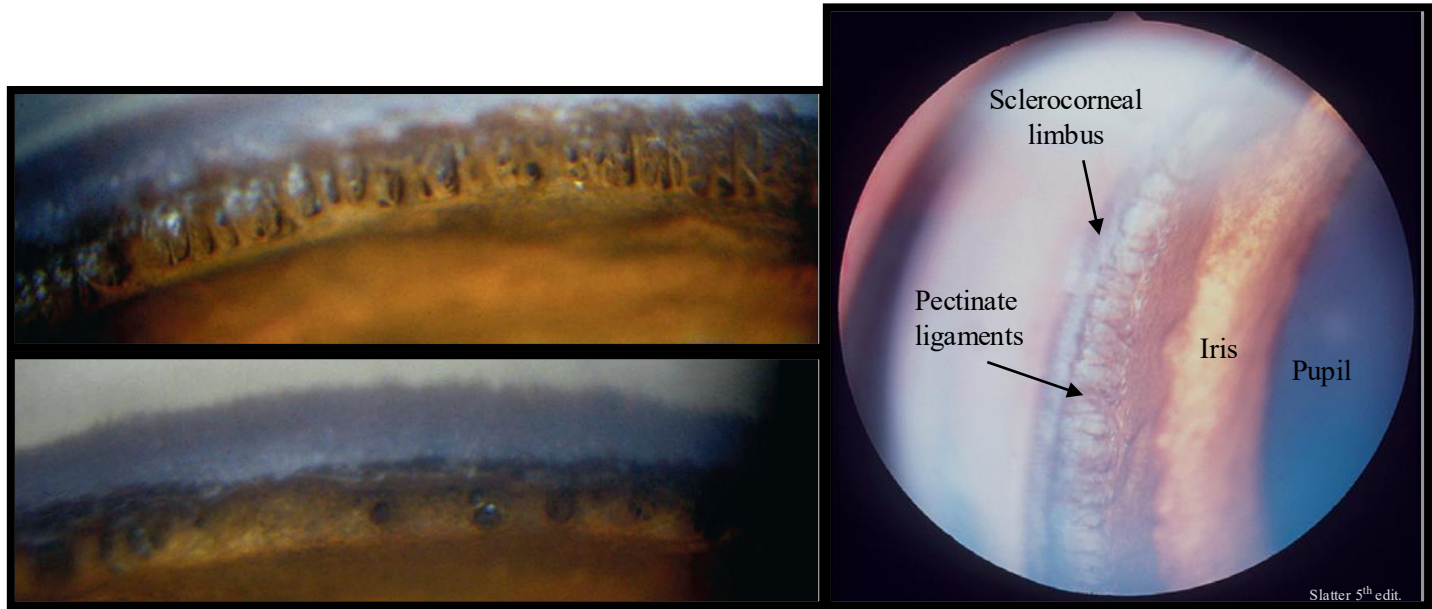
- **Gonioscopy**

- Visualization of the iridocorneal angle
- Gonioscopy lens: Koepple, Lovac-Barkan



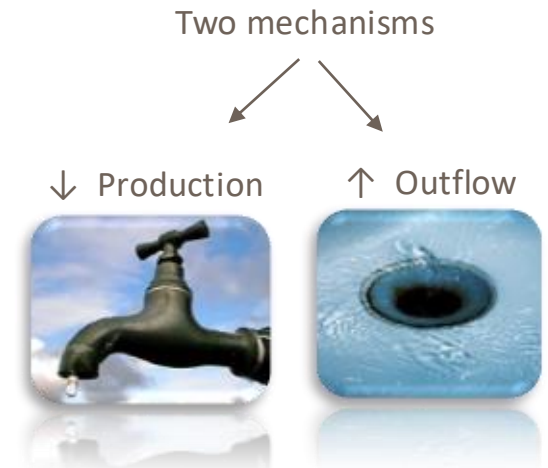
Diagnosis of primary glaucoma

- Gonioscopy



Common ocular emergencies

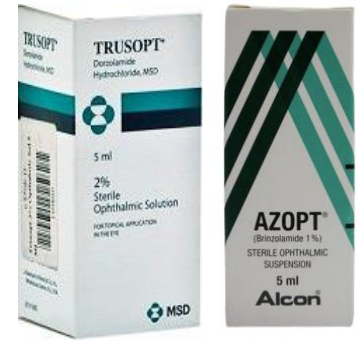- **Glaucoma: medical treatment**
- **Hyperosmotic diuretic agents (emergencies)**
 - Mannitol solution 10%-20% 1-2 g/kg IV for 20-30 minutes
 - ↓ IOP → dehydrates the vitreous (98% water)
 - **Intact blood-ocular barrier**
 - ↓ IOP in 10-15 minutes
 - Duration 6-10 hours
 - Do not offer water for 4 hours
 - **Secondary effects:** Dehydration
 - **Contraindications:** kidney failure or heart disease



Common ocular emergencies

- **Glaucoma: medical treatment**
- **Carbonic Anhydrase Inhibitors (CAIs)**
 - **Dorzolamide 2%, Brinzolamide 1%**
 - IOP is reduced by 20-30%
 - Maximum reduction may take 4 or 5 days
 - Oral treatment is no longer used due to its side effects:
 - Panting, anorexia, fatigue, depression, confusion, pressure ulcers (PU/PD), vomiting, diarrhea, thrombocytopenia

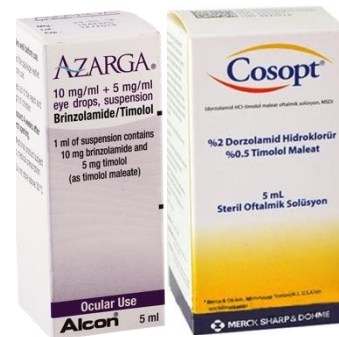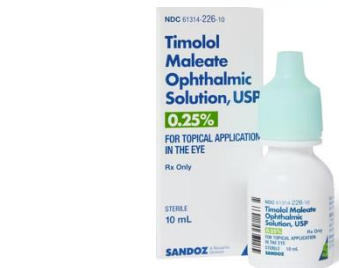↓ Production





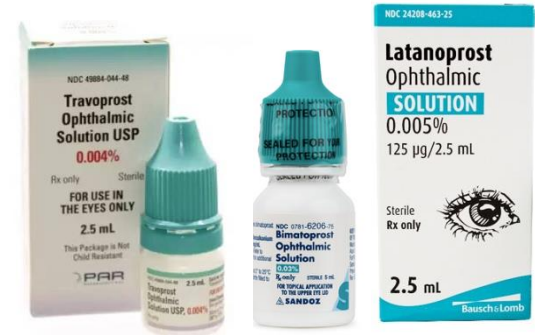
Common ocular emergencies

- Glaucoma: medical treatment
- Beta blockers
 - Timolol 0,25% and 0,5% (\downarrow 4-5 mmHg)
 - Blockade of β receptors \rightarrow processes of the ciliary body
 - Inhibition of active transport and ultrafiltration \rightarrow Na^+/K^+ -ATPase
 - Possible vasoactive action \rightarrow \downarrow blood flow in the ciliary body
 - Synergistic action when used together with other antiglaucoma drugs
 - Systemic absorption (0.25% < 10kg / 0.5% > 10kg)
 - Bradycardia and hypotension



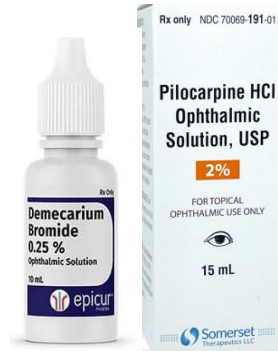
Common ocular emergencies

- Glaucoma: medical treatment
- Prostaglandin Analogs
 - Latanoprost 0.05%, Travoprost 0.004%, Bimatoprost 0.03%
 - ↓ IOP 40-50%
 - Rapid effect: 10-15 m
 - Miosis
 - Contraindication in secondary glaucoma
 - Uveitis, anterior lens luxation



Common ocular emergencies

- **Glaucoma: medical treatment**
- **Parasympathomimetic (Miotics)**
 - Secondary effects: ocular irritation, uveitis
 - Systemic: salivation, vomiting, diarrhea, sweating
 - **Direct parasympathomimetic**
 - **Pilocarpine 1%-2%: ocular irritation**
 - **Indirect parasympathomimetic**
 - **Demecarium Bromide 0,125-0,25 %**
 - Drug compound, prophylactic in primary glaucoma



Primary glaucoma: medical treatment

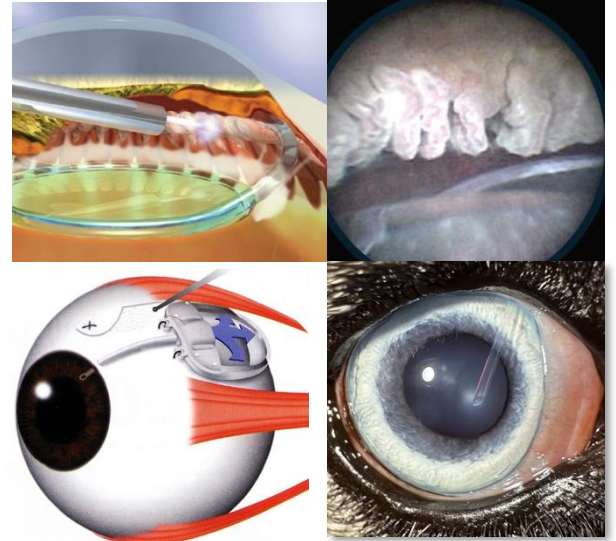
- **Affected eye**
 - Apply a drop of **Latanoprost** and recheck IOP in 30 m
 - IOP > 30 mmHg, apply a drop of **Dorzolamida/timolol?** and recheck the IOP in 30 m
- IOP ≤ 20 mmHg, continue medical treatment
- IOP >30 mmHg after several drops of antiglaucoma, consider enucleation
- Analgesia and nonsteroidal anti-inflammatory drug (NSAID)



≤ 20 mm Hg in dogs

Common ocular emergencies

- **Glaucoma: surgical treatment**
- **Techniques for reducing aqueous production**
 - Laser cyclophotocoagulation
 - Cyclocryotherapy
 - Pharmacological ablation of the ciliary body
- **Techniques for increasing aqueous outflow**
 - Drainage implant surgery
 - Ahmed or Baerveldt implant
- **Enucleation or pharmacologic ciliary body ablation**



Common ocular emergencies

- **Glaucoma: surgical treatment**



ORIGINAL ARTICLE

Bilateral enucleation in dogs: A review of owner perceptions and satisfaction

Negar Hamzianpour, Kinley Smith, Charlotte Dawson, Michael Rhodes ✉

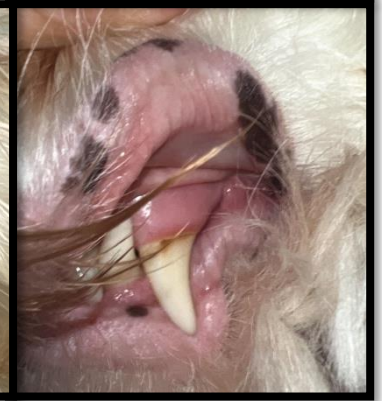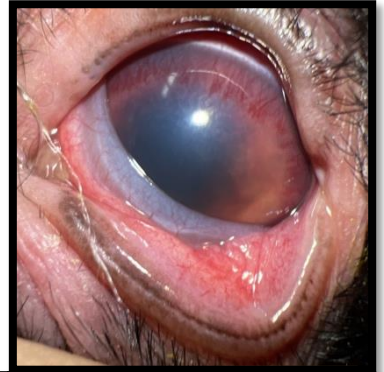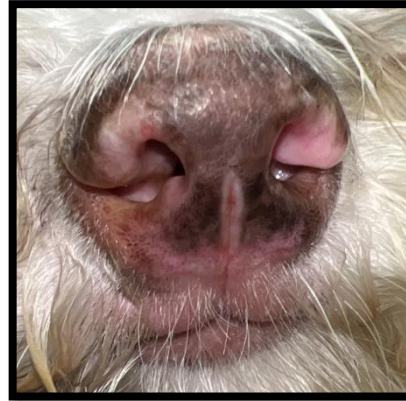
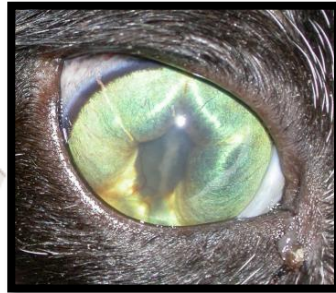
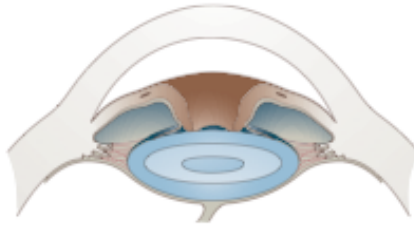
Comparative Study > [Vet Rec. 2021 Apr;188\(7\):e53. doi: 10.1002/vetr.53. Epub 2021 Jan 24.](#)

Comparing the behaviour of dogs before and after enucleation due to glaucoma

Jesus Diaz Bujan ¹, Emma J Boyd ², Roser Tetas Pont ¹

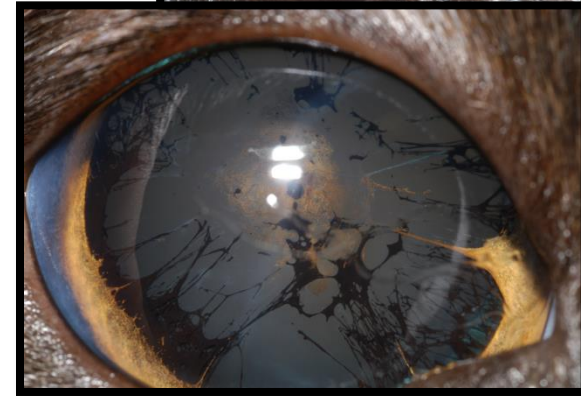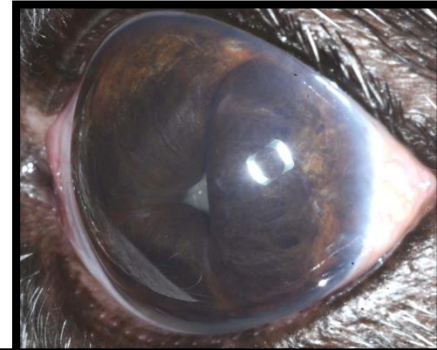
Secondary glaucoma: Uveitis

- Trauma
- Infection (bacterial, viral, parasitic)
- Autoimmune diseases
 - Uveodermatologic syndrome
- Iris bombe (360° posterior synechia)



Secondary glaucoma: Uveitis

- Medical treatment:
 - Diagnose and treat the underlying cause
 - Carbonic anhydrase inhibitors with beta-blockers
 - **Avoid miotic agents or those that cause uveitis**
 - Latanoprost, pilocarpine and demecarium bromide
 - They can worsen glaucoma!
 - There are always exceptions to the rule!



Ocular emergencies

- Ophthalmic examination
 - Instruments and tests
 - Schirmer tear test (STT-1)
 - Tonovet
 - Fluorescein test
- Common ocular emergencies
 - Acute glaucoma
 - Uveitis
 - Lens luxation
 - Sudden blindness
 - Retrobulbar abscess/cellulitis
 - Globe proptosis

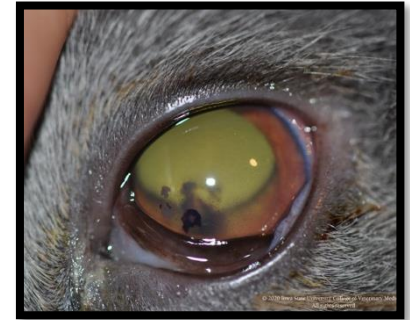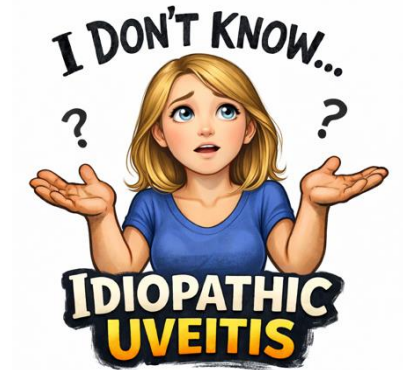
Uveitis

- Primary ocular vs. non-ocular causes
 - Trauma
 - Neoplasia
 - Lens-Induced
 - Infectious
 - Immune-Mediated
 - Idiopathic

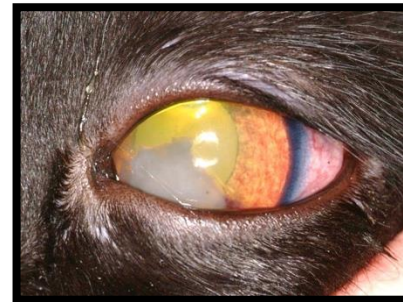CAUSE	MOST COMMONLY AFFECTED SPECIES	CAUSE	MOST COMMONLY AFFECTED SPECIES
NEOPLASTIC AND PARANEOPLASTIC			
Lymphosarcoma	Any	Canine adenovirus types 1 and 2 (immune-mediated)	Dog
Melanoma	Dog, cat	Canine distemper virus	Dog
Histiocytic proliferative disease	Dog	Coronavirus (feline infectious peritonitis)	Cat
Hyperviscosity syndrome	Dog	Feline leukemia virus	Cat
Granulomatous meningoencephalitis	Dog	Feline immunodeficiency virus	Cat
Miscellaneous primary intraocular tumors	Any	Herpesvirus (Marek's disease)	Chickens, turkeys
Miscellaneous metastatic tumors	Any	Herpesvirus	
		Feline herpesvirus 1	Cat
METABOLIC			
Diabetes mellitus (lens-induced uveitis)	Dog	Canine herpesvirus 1	Dog
Systemic hypertension	Cat, dog	Equine herpesvirus 1 and 2	Horse
Hyperlipidemia	Dog	Ovine herpes virus 2 (MCF)	Cattle
Coagulopathies	Any	Alcelaphine herpesvirus 1 (MCF)	Cattle
		Rabies virus	Dog
IDIOPATHIC			
	Any	Equine influenza	Horse
		Equine viral arteritis	Horse
		Parainfluenza type 3	Horse
		MCF	Cattle
IMMUNE-MEDIATED			
Cataracts (lens-induced uveitis)	Any	Parasitic	
Lens trauma (phacoclastic uveitis)	Any	<i>Taenia multiceps</i>	Sheep, dog
Immune-mediated thrombocytopenia	Any	<i>Echinococcus granulosus</i>	Horse (rare)
Immune-mediated vasculitis	Any	<i>Angiostrongylus vasorum</i>	Dog
Uveodermatologic syndrome (Vogt-Koyanagi-Harada-like syndrome)	Dog	<i>Dirofilaria immitis</i>	Dog
		<i>Setaria</i> spp.	Horse
		<i>Onchocerca cervicalis</i>	Horse (equine recurrent uveitis)
INFECTIOUS			
		<i>Strongylus</i>	Horse
Algae		<i>Diptera</i> spp. (ophthalmomyiasis interna)	Various
<i>Geotricha</i> spp.	Dog	<i>Toxocara</i> spp., <i>Baylisascaris</i> spp. (ocular larval migrans)	Dog, cat, sheep and goats
<i>Prototheca</i> spp.	Dog	<i>Trypanosoma</i> spp.	Cat
		<i>Elaeophora schneideri</i>	Sheep and goats
Bacteria		TOXIC	
Septicemia or endotoxemia resulting from any cause	Any	Drugs	
<i>Leptospira</i> spp.	Dog, horse	Pilocarpine, carbachol other	Any
<i>Bartonella</i> spp.	Dog, cat	Prostaglandin derivatives (latanoprost)	Any
<i>Borrelia burgdorferi</i>	Dog, horse	Sulfamethazine and trimethoprim (immune-mediated)	Dogs
<i>Brucella</i> spp.	Dog, horse	Endotoxemia from any systemic source	Any
<i>Escherichia coli</i>	Cattle, horse	Infectious keratitis with bacterial toxin production	Any
<i>Streptococcus</i> spp.	Horse	Radiation therapy	Any
<i>Rhodococcus equi</i>	Horse	TRAUMA	
<i>Listeria monocytogenes</i>	Sheep, cattle	Blunt or penetrating injuries	Any
<i>Haemophilus</i> spp.	Cattle	Corneal foreign bodies	Any
Tuberculosis	Cattle, cat	REFLEX UVEITIS	
<i>Ehrlichia canis</i> or <i>Ehrlichia platys</i>	Dog	Ulcerative keratitis of any cause	Any
<i>Rickettsia rickettsii</i>	Dog	Deep necrotizing or nonnecrotizing scleritis	Dog
		Episcleritis	Dog
Protozoa			
<i>Toxoplasma gondii</i> *	Any		
<i>Leishmania donovani</i>	Dog		
Yeasts and Fungi			
<i>Aspergillus</i> spp.	Chickens, turkeys, cat		
<i>Blastomyces</i> spp.	Dog, cat		
<i>Coccidioides immitis</i>	Dog		
<i>Cryptococcus</i> spp.	Dog, cat		
<i>Histoplasma capsulatum</i>	Dog, cat		
<i>Pseudallescheria boydii</i>	Dog		

Uveitis Work-Up

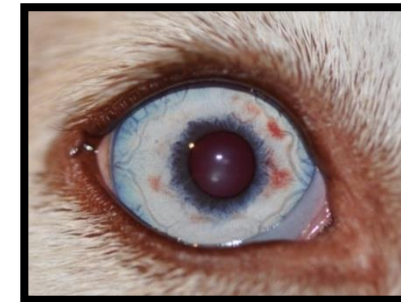
- **Complete ocular exam**
 - Document and grade findings
 - Exclude primary ocular cause
- **Complete physical exam**
 - Systemic disease?
 - Investigate abnormalities
- **Additional diagnostic tests?**
 - CBC, chemistry panel, urinalysis
 - Infectious disease testing
 - Lymph node aspirate
 - Thoracic and/or abdominal imaging
 - Ocular ultrasound +/- aspirate



Feline Infectious Peritonitis



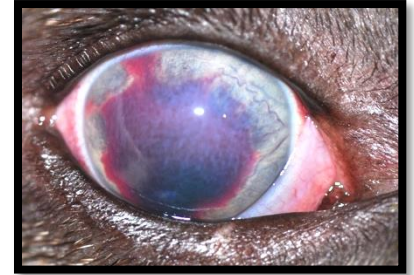
Histoplasmosis



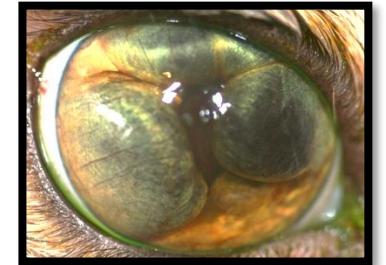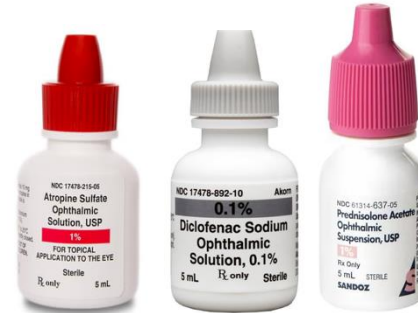Rocky Mountain Spotted Fever

Uveitis Treatment

- Start treatment immediately +/- submit labwork
- Topical (QID+) and systemic anti-inflammatory drugs
 - Treat eye aggressively at first, then taper medications as signs resolve
 - Recheck in 1 week to modify plan
 - Treat 2-4 weeks past resolution of signs
- Topical mydriatic
 - Atropine SID-BID
 - Tropicamide TID-QID
- Address underlying cause!



Hyphema, avoid NSAIDs



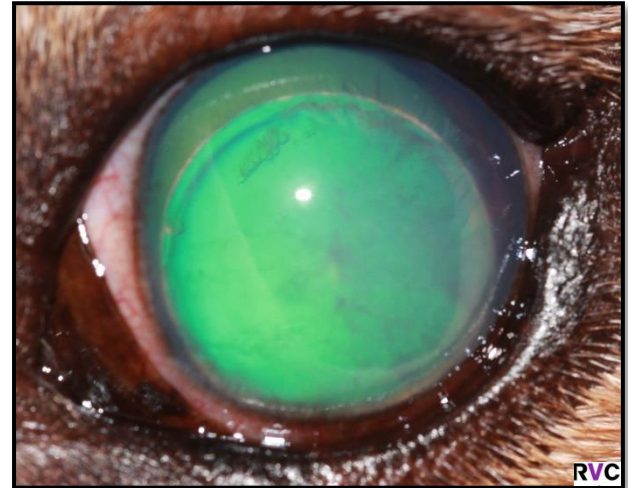
Iris bombe

Ocular emergencies

- Ophthalmic examination
 - Instruments and tests
 - Schirmer tear test (STT-1)
 - Tonovet
 - Fluorescein test
- Common ocular emergencies
 - Acute glaucoma
 - Uveitis
 - Lens luxation
 - Sudden blindness
 - Retrobulbar abscess/cellulitis
 - Globe proptosis

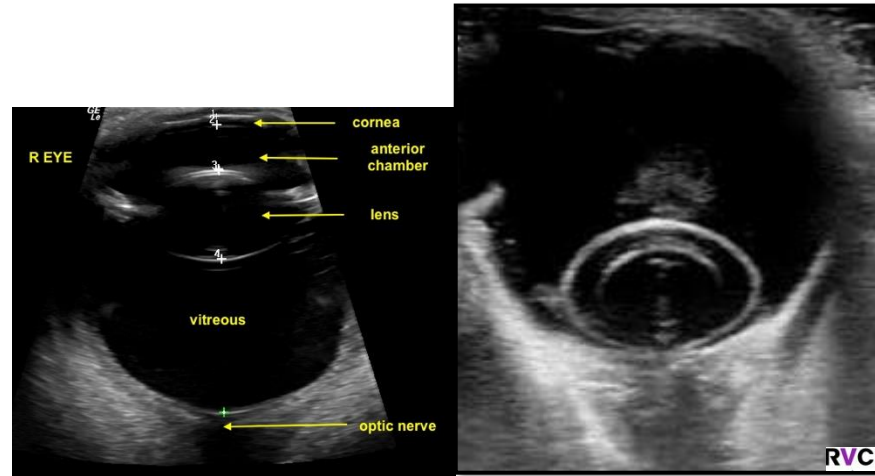
Common ocular emergencies

- **Lens luxation**
- **Primary**
 - Inherited (terrier breeds)
- **Secondary**
 - Glaucoma
 - Uveitis
 - Trauma
- **Anterior or posterior luxation**
 - **Latanoprost is contraindicated in anterior lens luxation**



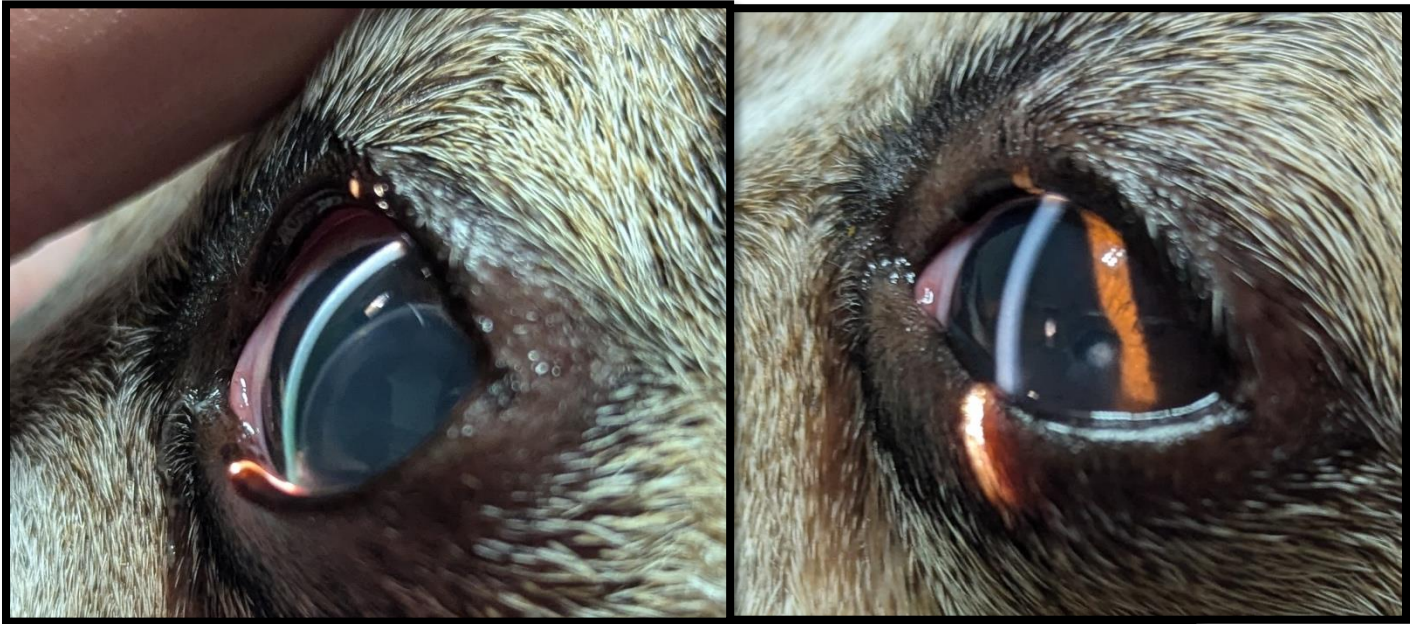Common ocular emergencies

- **Lens luxation**
- **Medical**
 - Trans-corneal reduction of anterior lens luxation (TR-ALL) “Couching”
 - Latanoprost BID long-term
- **Surgery**
 - Lens removal
 - Phacoemulsification or Intracapsular lens extraction (ICLE)



Secondary glaucoma: Anterior lens luxation

- Transcorneal reduction of the anterior lens luxation “Couching”

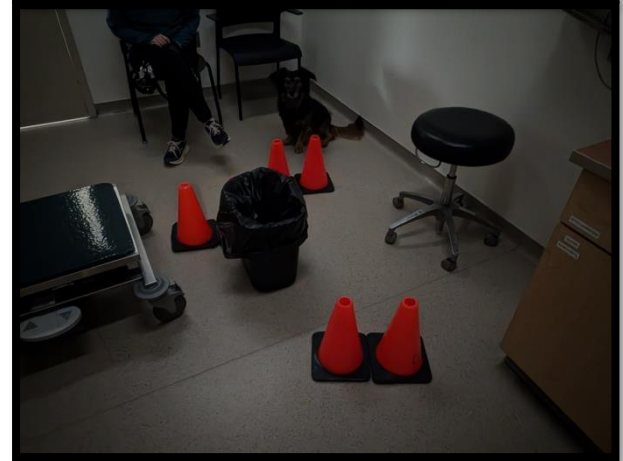

Ocular emergencies

- Ophthalmic examination
 - Instruments and tests
 - Schirmer tear test (STT-1)
 - Tonovet
 - Fluorescein test
 - Slit lamp
- **Common ocular emergencies**
 - Corneal foreign body
 - Corneal ulceration
 - Acute glaucoma
 - Lens luxation
 - **Sudden blindness**
 - Retrobulbar abscess/cellulitis
 - Globe proptosis

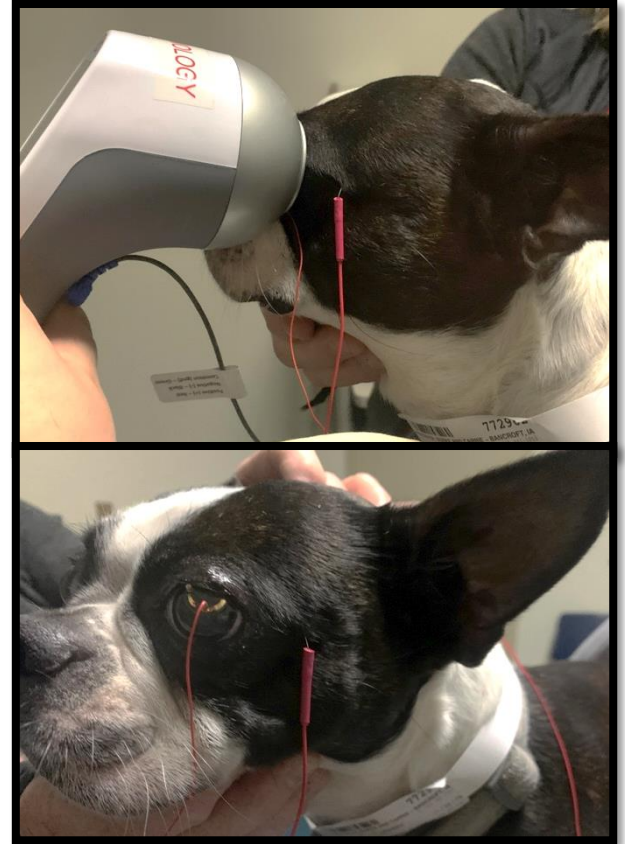Common ocular emergencies

- Sudden blindness
- How to assess the vision?
 - Menace response
 - Visual tracking
 - Maze test
 - Visual placing



Common ocular emergencies

- Sudden blindness
- Ophthalmic vs neurological?
 - Full ophthalmic examination (retinal disease, cataract formation, etc)
 - IOP measurement
 - Neurological exam, further test required
 - Electroretinogram (ERG)
 - MRI



Acute onset blindness

Neurologic signs

Ophthalmic signs
(other than PLR deficits)

Further neuro & ophthalmic investigation

- Cataracts
- Retinal detachment: systemic hypertension
- Optic nerve disease
- Central blindness: MUO/A, GME

IOP elevated?
Glaucoma

No neuro signs

+/- PLR deficits
No (other) ocular signs

Specific investigation:
ERG

Negative: SARDs
or IMR

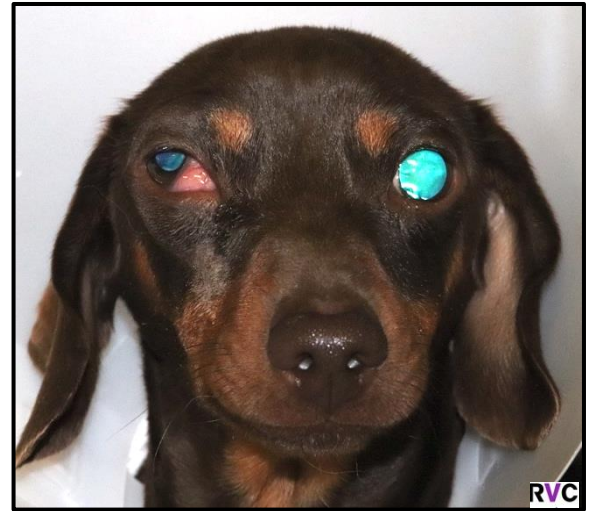Positive: advanced
imaging
(Central blindness)

Ocular emergencies

- Ophthalmic examination
 - Instruments and tests
 - Schirmer tear test (STT-1)
 - Tonovet
 - Fluorescein test
- **Common ocular emergencies**
 - Corneal foreign body
 - Corneal ulceration
 - Acute glaucoma
 - Lens luxation
 - Sudden blindness
 - **Retrobulbar abscess/cellulitis**
 - Globe proptosis

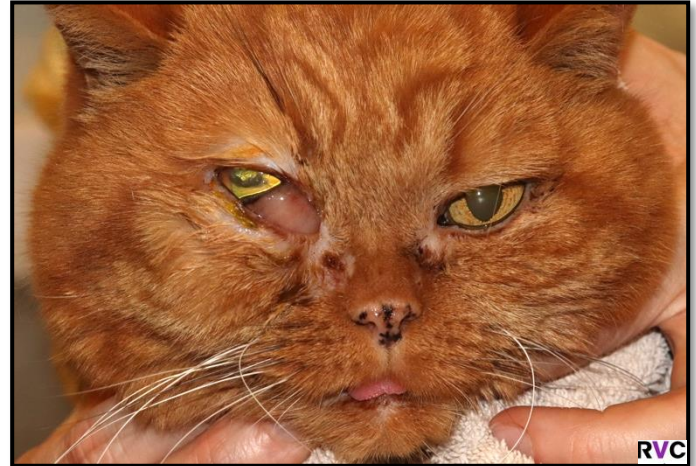Common ocular emergencies

- **Retrobulbar abscess/cellulitis**
 - Exophthalmos
 - Strabismus
 - Protrusion of the nictitating membrane
 - Periocular swelling
 - Epiphora or mucopurulent discharge
 - Lagophthalmos
 - Pain or difficulty in opening the mouth



Common ocular emergencies

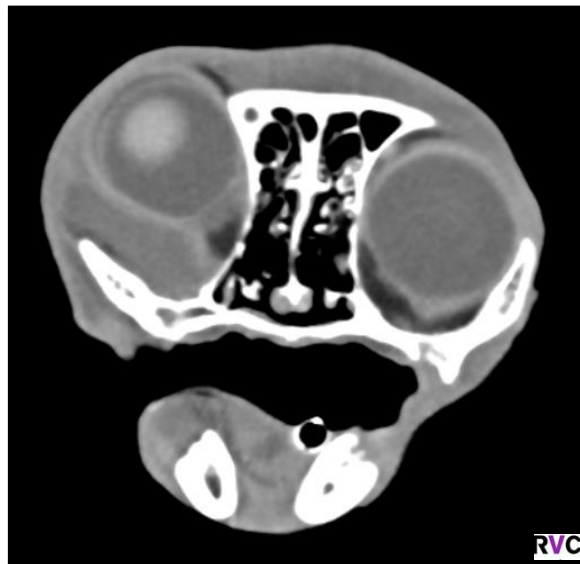- Retrobulbar abscess/cellulitis
 - Increase IOP
 - Retinal fold or scleral indentation
 - Papilloedema



Common ocular emergencies

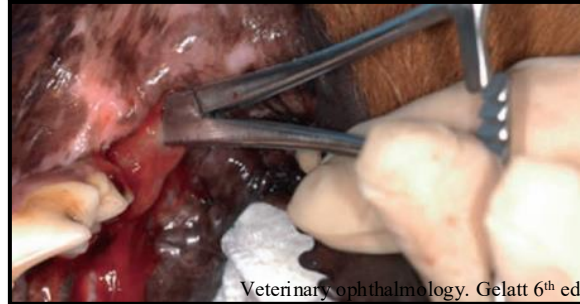
- Retrobulbar abscess/cellulitis
- Further investigation
 - CT vs MRI
 - Ocular ultrasound?
- Medical treatment
 - Systemic NSAIDS
 - Systemic Antibiotics?
 - Pain relief
 - Eye lubrication
 - Soft food

CT scan of
the head



RVC

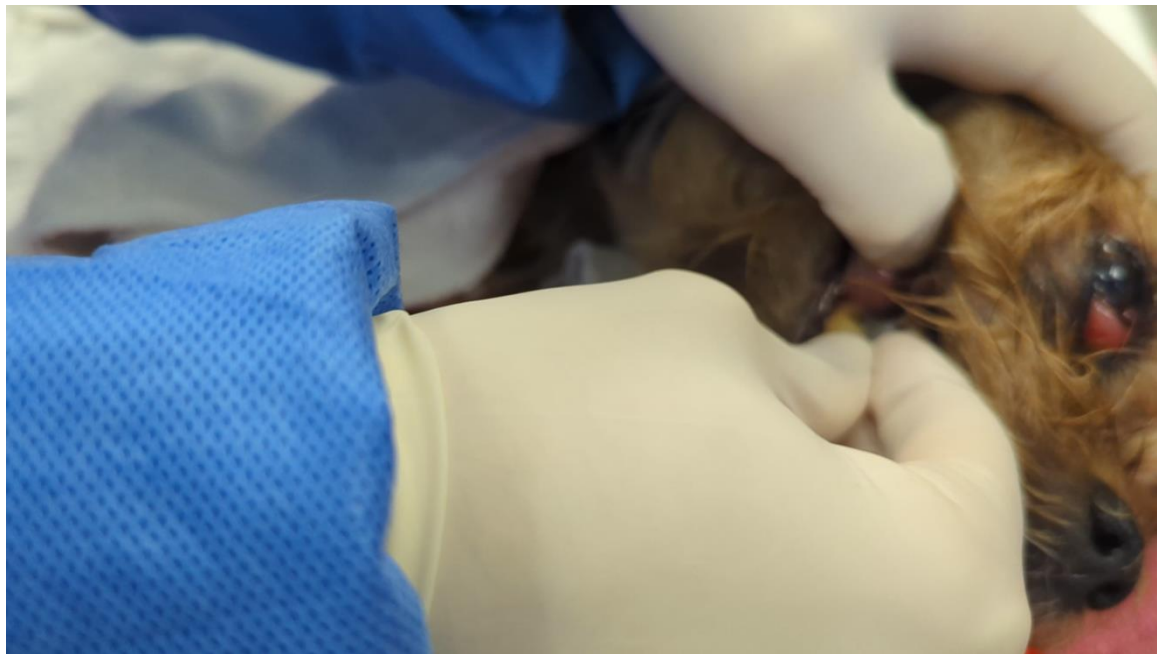Abscess drainage
caudal to the last
upper molar



Veterinary ophthalmology. Gelatt 6th ed.

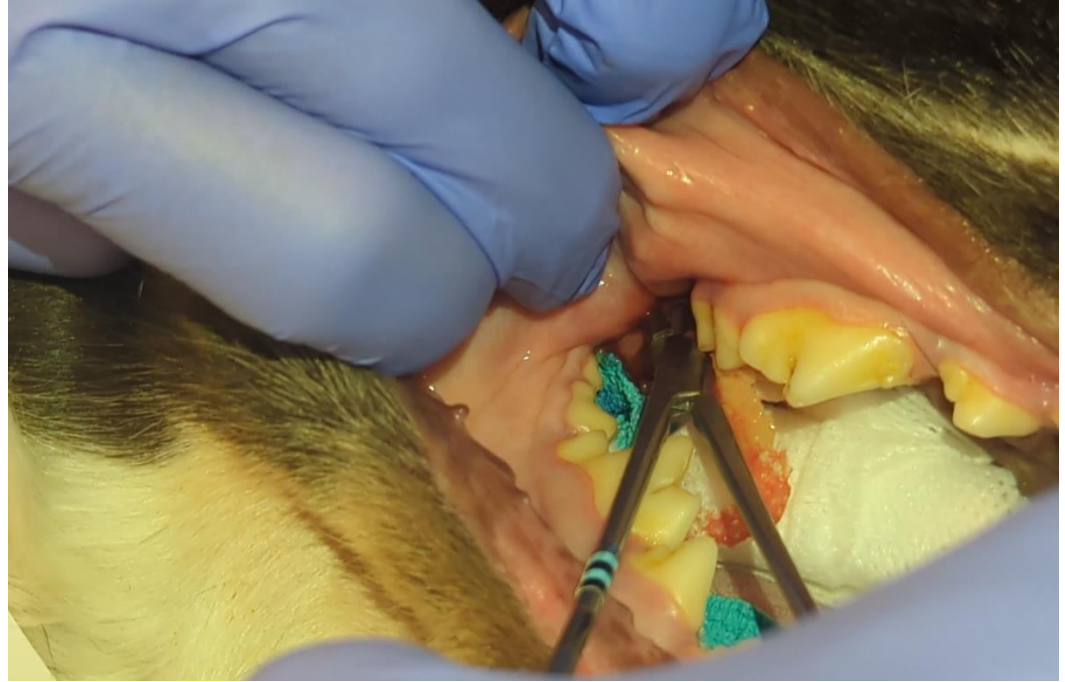Common ocular emergencies

- Retrobulbar abscess/cellulitis



Common ocular emergencies

- Retrobulbar abscess/cellulitis

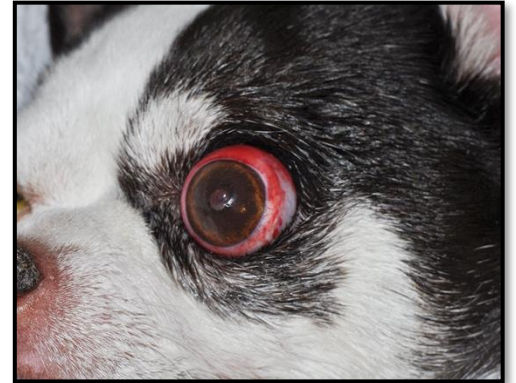

Ocular emergencies

- Ophthalmic examination
 - Instruments and tests
 - Schirmer tear test (STT-1)
 - Tonovet
 - Fluorescein test
- **Common ocular emergencies**
 - Corneal foreign body
 - Corneal ulceration
 - Acute glaucoma
 - Lens luxation
 - Sudden blindness
 - Retrobulbar abscess/cellulitis
 - **Globe proptosis**

Common ocular emergencies

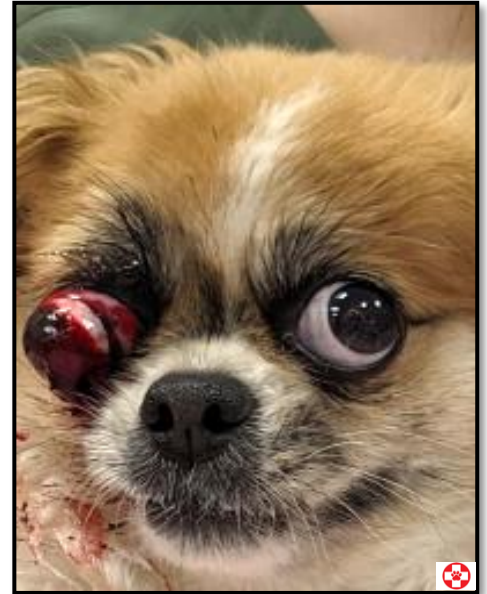- **Globe proptosis:** Sudden, forward displacement of the globe with entrapment of the eyelids behind the equator
- **No spontaneous repositioning** of the globe.
- **True ophthalmic emergency**, which requires immediate medical and surgical therapy.
- Even if vision cannot be preserved, the globes can often be salvaged for cosmetic purposes



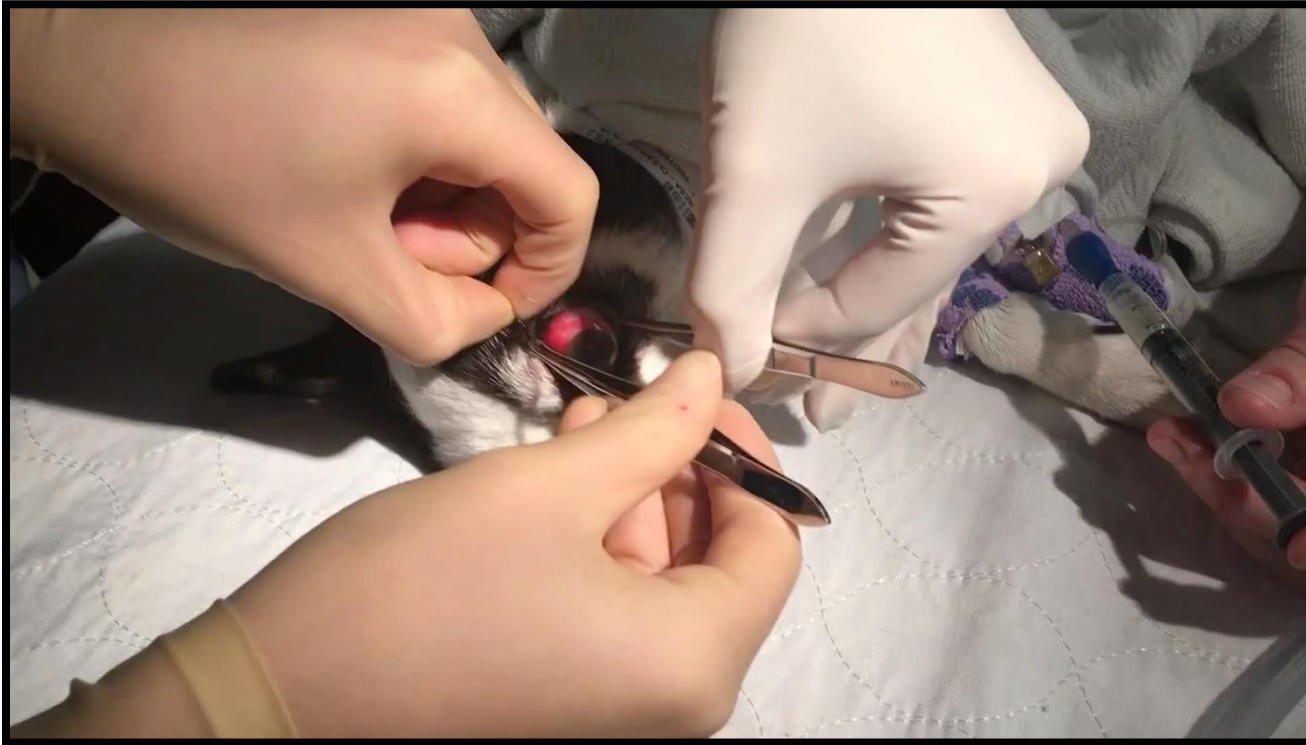
<https://todaysveterinarypractice.com/ophthalmology/ocular-proptosis/>

Common ocular emergencies

- **Temporary tarsorrhaphy**
- **1–3 horizontal mattress sutures** (nylon 5-0 or 6-0)
- **Not to penetrate the palpebral conjunctiva**
- **Stents** (IV tubing, rubber band, or buttons) prevent pressure necrosis of the skin
- After weeks, the sutures are removed (the medial first; if there is still an apparent tendency to luxation)



Common ocular emergencies



https://vimeo.com/364872066?embedded=true&source=vimeo_logo&owner=103695867

Summarize

- Systematic ophthalmic examination
- Medical treatment of glaucoma aims for an IOP ≤ 20 mmHg
- Latanoprost is contraindicated in anterior lens luxation
- Globe proptosis requires immediate surgical therapy



ANY QUESTIONS?



IOWA STATE UNIVERSITY

"It does not matter how slowly you go as long as you do not stop." - Confucius