

FAST AND BEYOND:
HOW TO MAKE YOUR ULTRASOUND A
PROFITABLE AND USEFUL TOOL IN PRACTICE

Julie Riha, DVM
Assistant Clinical Professor
Emergency and Critical Care Department
Iowa State University

OBJECTIVES

- Overview of many uses of ultrasound in practice
- Valuable diagnostic tools
- Operator can have limited skills in ultrasonography



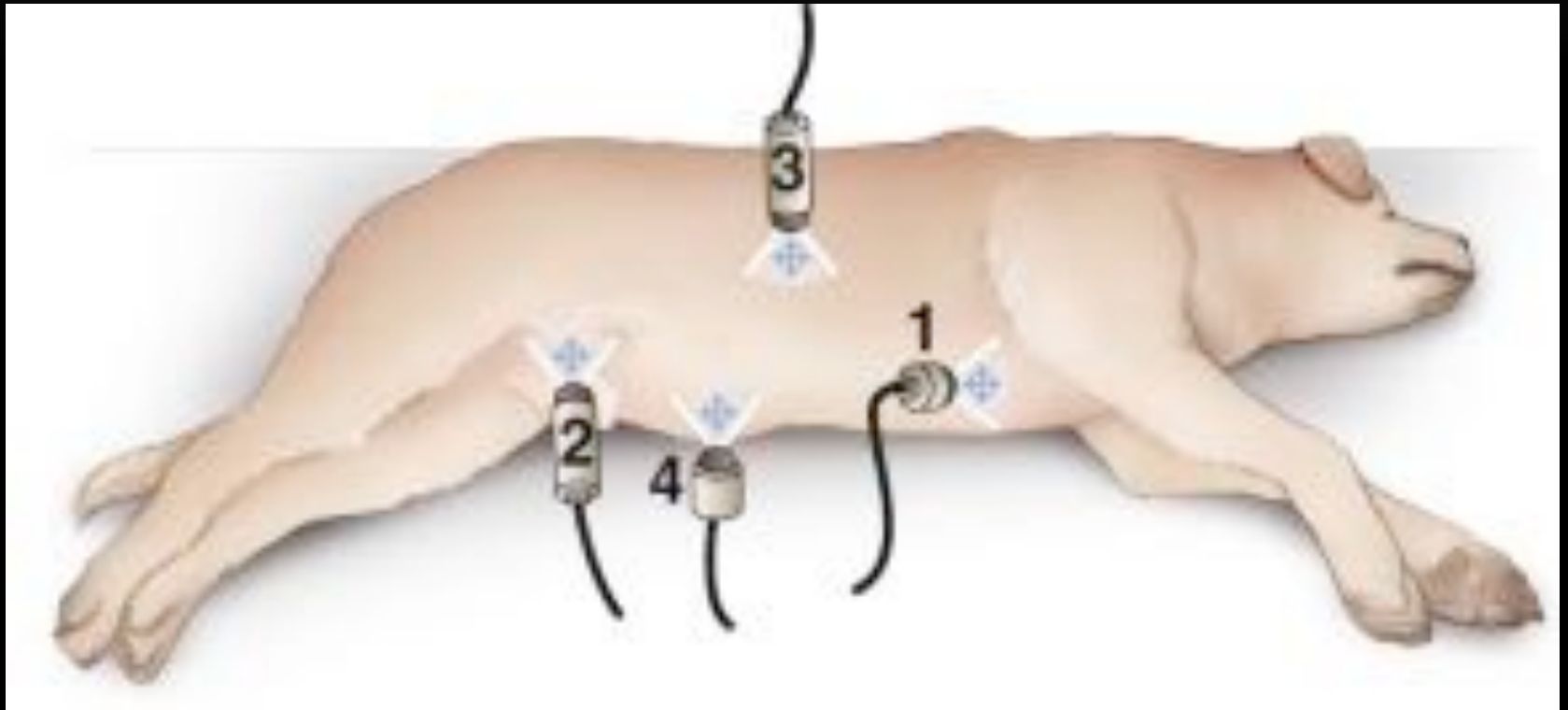ULTRASOUND BASIC REMINDERS

- “Echogenicity” ability to reflect US waves compared to the surrounding tissues
 - Contrast differences = the images you view
 - Hyperechoic= white
 - Hypoechoic=grey
 - Anechoic= black (bone, fluid, fat)

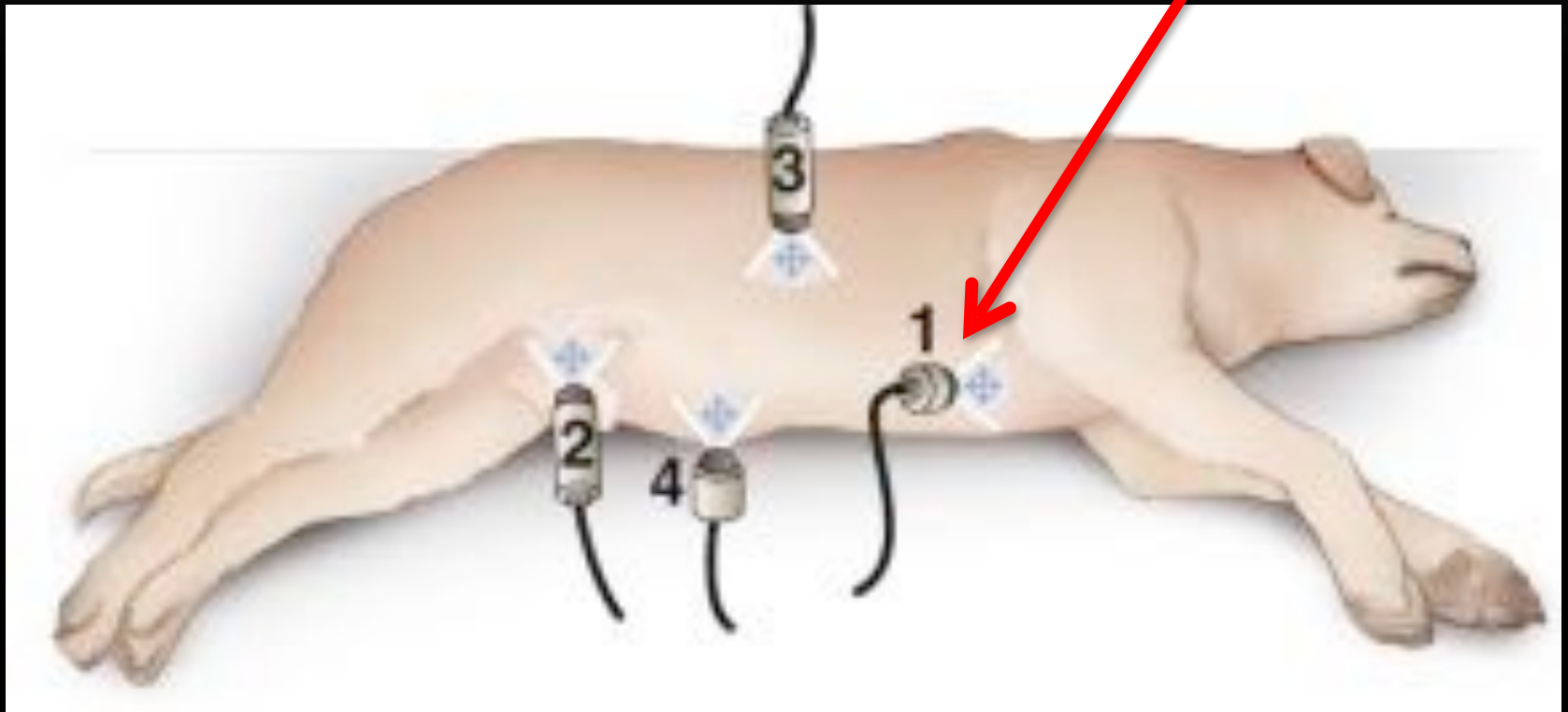
FAST: FOCUSED ASSESSMENT WITH SONOGRAPHY FOR TRAUMA

- Not a replacement for full abdominal ultrasound to evaluate all organs
- Brief evaluation to be performed within a few minutes
- Detect positive fluid findings
 - Abdominocentesis, thoracocentesis
- Monitor resolution/worsening of conditions
- ISU client charge \$45

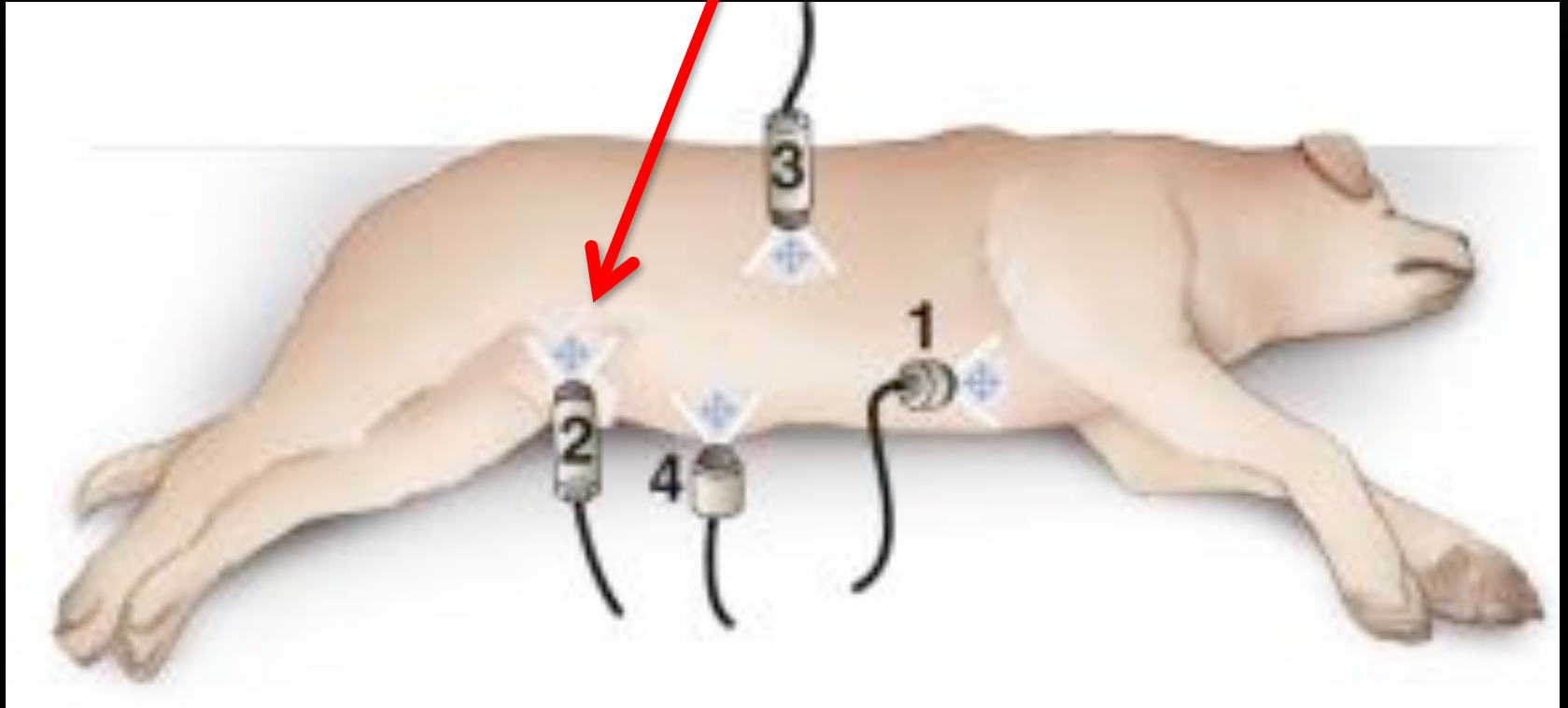
AFAST



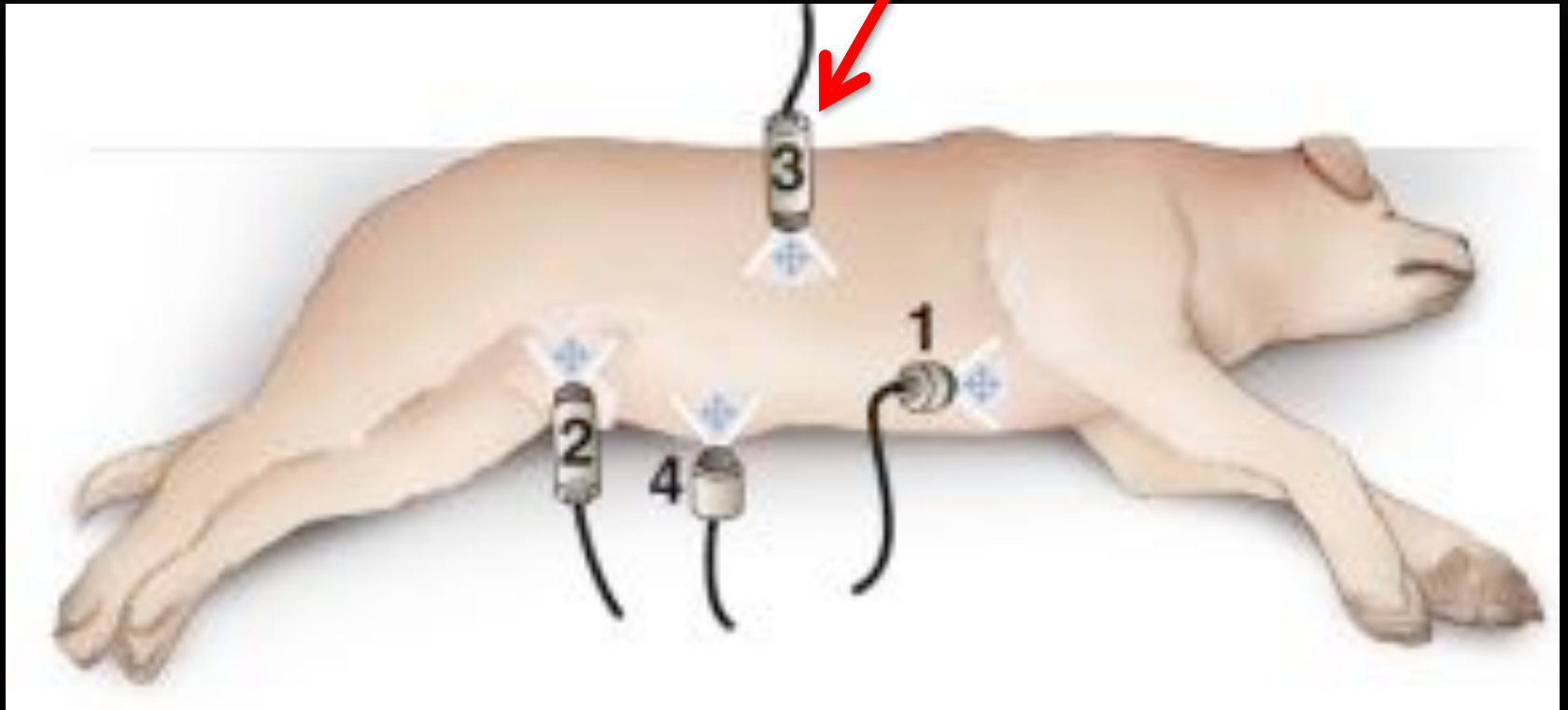
AFAST



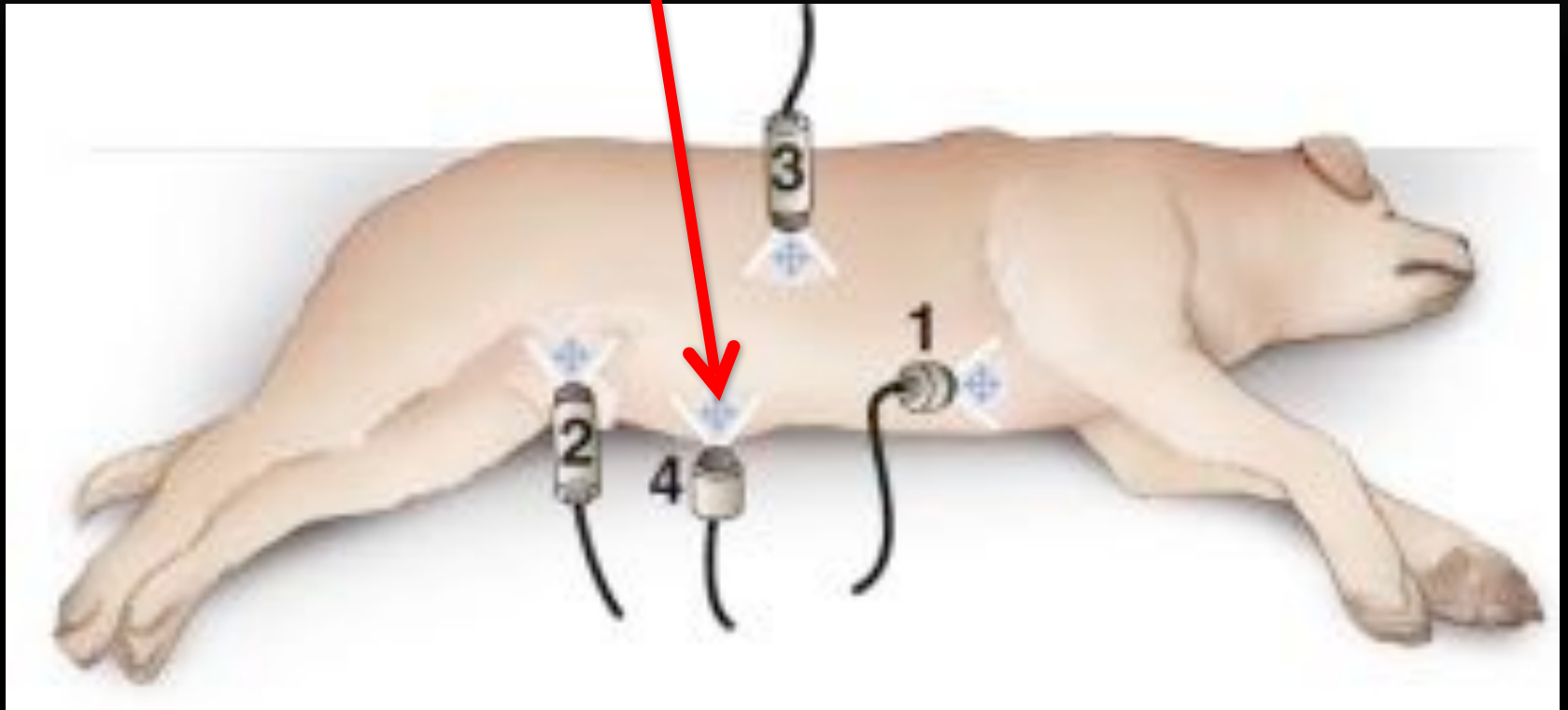
AFAST



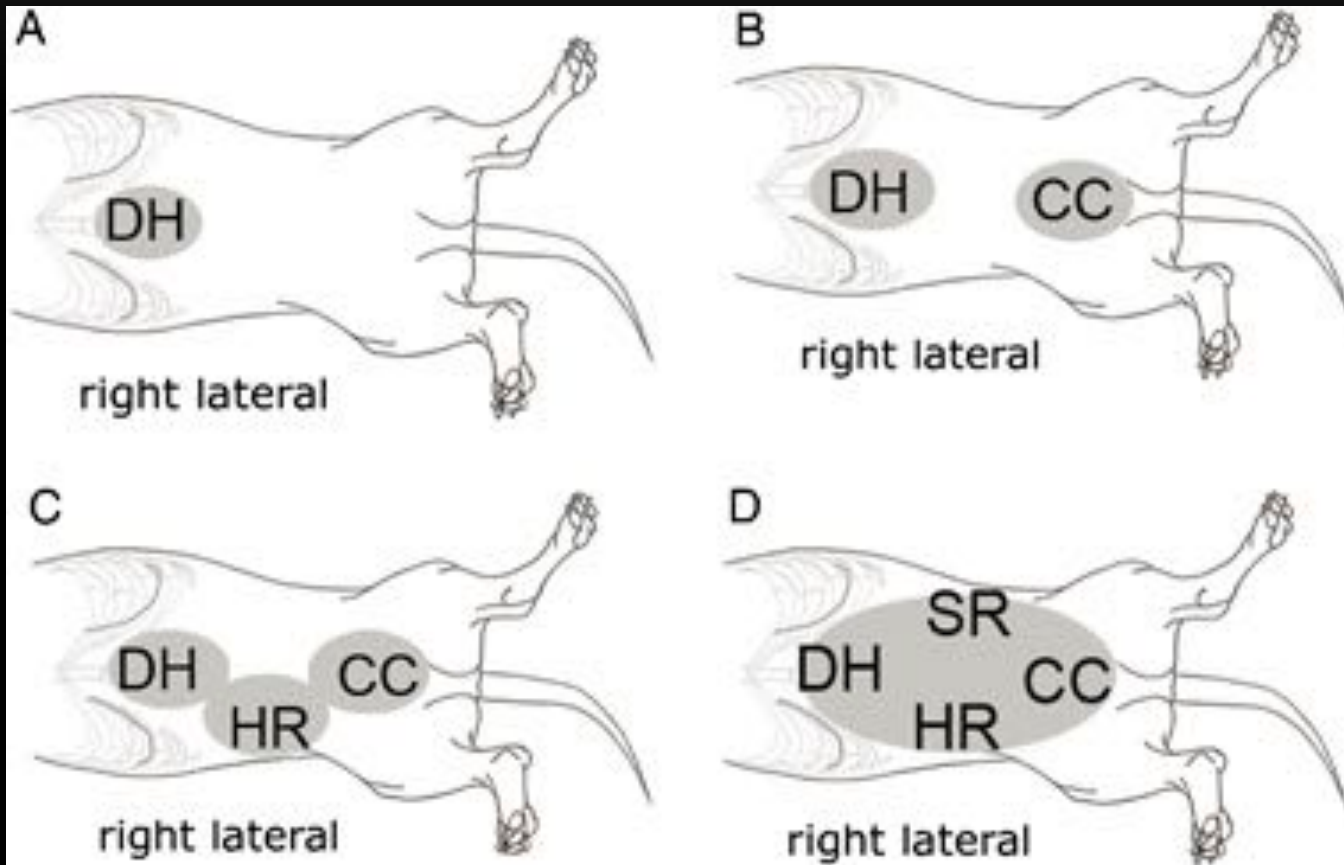
AFAST



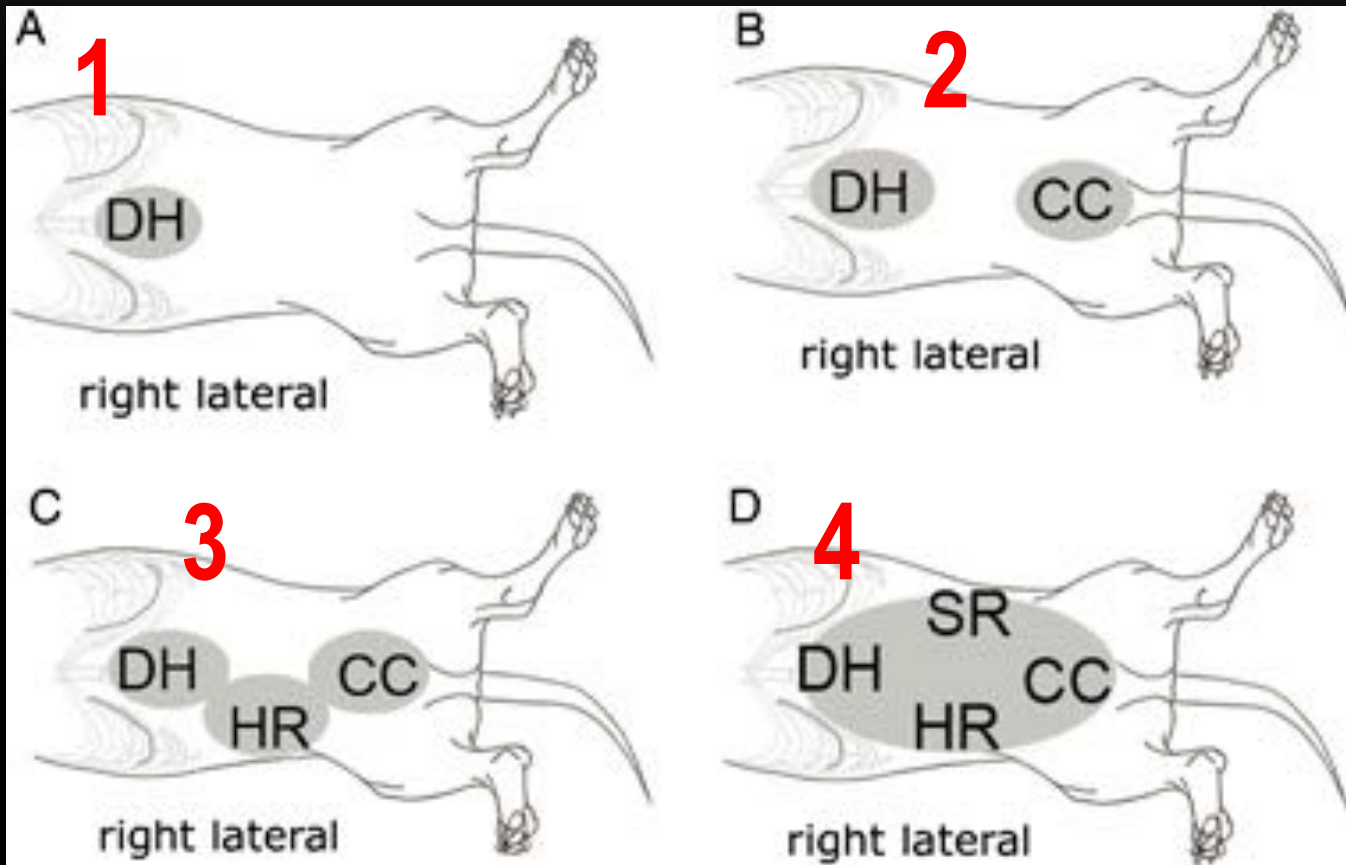
AFAST



FLUID SCORING



FLUID SCORING



ABDOMINAL FLUID SCORING

Original Study

Journal of Veterinary Emergency and Critical Care 19(5) 2009. pp 426–437
doi 10.1111/j.1476-4431.2009.00459.x

Evaluation of an abdominal fluid scoring system determined using abdominal focused assessment with sonography for trauma in 101 dogs with motor vehicle trauma

Gregory R. Lisciandro, DVM, DABVP, DACVECC; Michael S. Lagutchik, DVM, MS, DACVECC; Kelly A. Mann, DVM, MS, DACVR; Geoffrey T. Fosgate, DVM, PhD, DACVPM; Elizabeth G. Tiller, DVM; Nicholas R. Cabano, DVM; Leslie D. Bauer, DVM; Bradley P. Book, DVM, DABVP and Philip K. Howard, DVM

AFS SCORING AS A PREDICTOR FOR ANEMIA IN TRAUMA

- Abdominal fluid score (AFS) 3 or 4
 - Normal PCV on intake → 20% decrease from initial PCV
 - PCV <25% correlated with animals scoring a 3,4
- Abdominal fluid score (AFS) 1, 2
 - Only one animal in the study (101 subjects) became clinically anemic (PCV <30%)
 - Useful to perform serial examinations, Q4-6hrs



CYSTOCENTESIS

- Cystocolic view
- Evaluate bladder wall, contents prior to aspiration
- Obtain a sterile sample for culture analysis
- Any mass detected in UB
 - Cytology recommended
 - polypoid cystitis vs TCC vs other
- ISU client charge \$26

TIELBUR, MATT, BO 737256

ISU VET HOSPITAL EP1076 LC 02/25/2019 09:19:06PM

ISU ABD

TICO.3 MI 0.8

CB-5
52Hz
RS

2D
5.2"
Dyn R 55
P Med
Gen

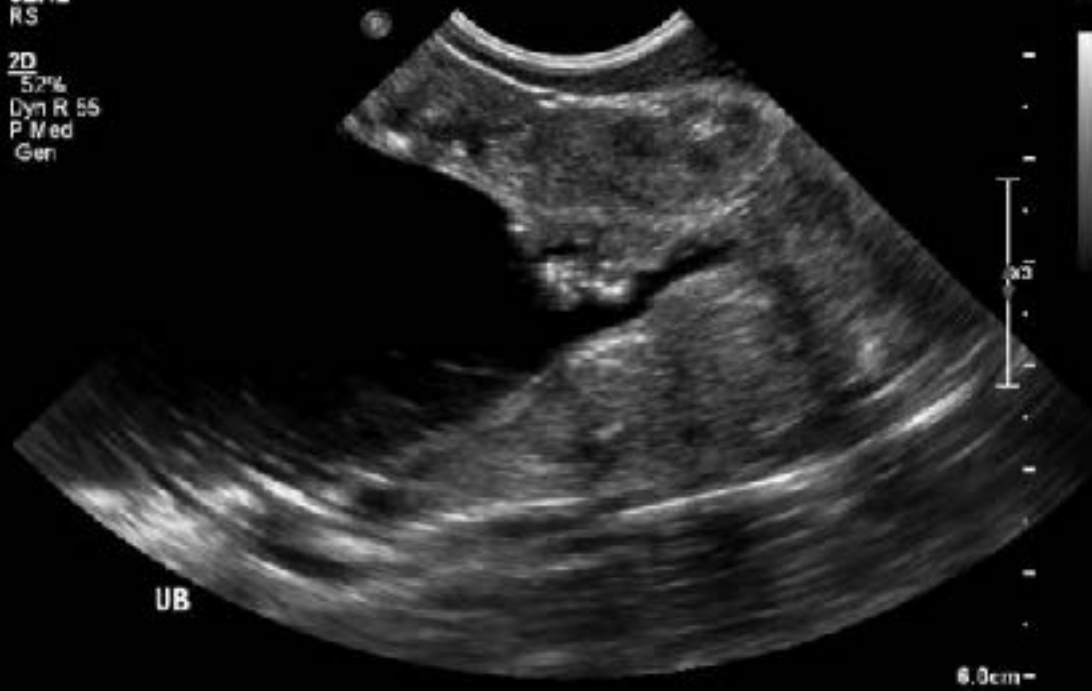

Photo credit: K. Cooley, DVM

ISU ABD

C8-6

52Hz

RS

2D

52%

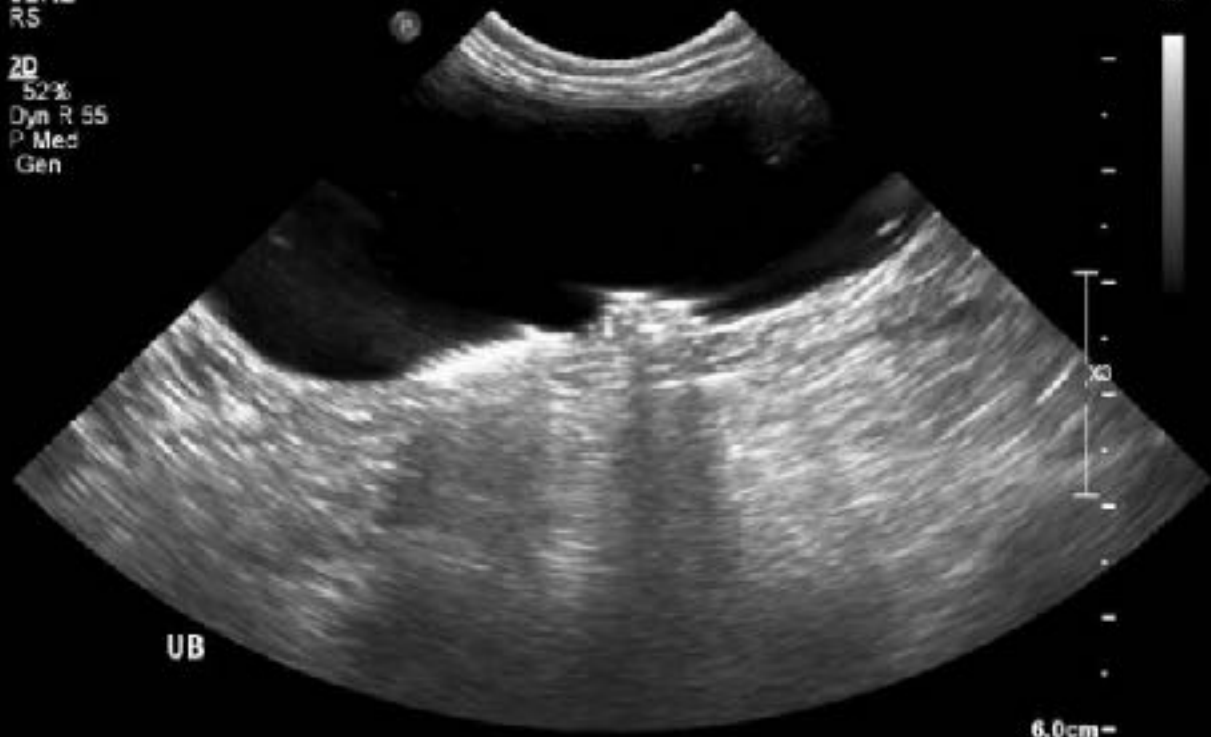Dyn R 55

P Med

Gen

TIC 0.3 MI 0.8

M3



UB

6.0cm



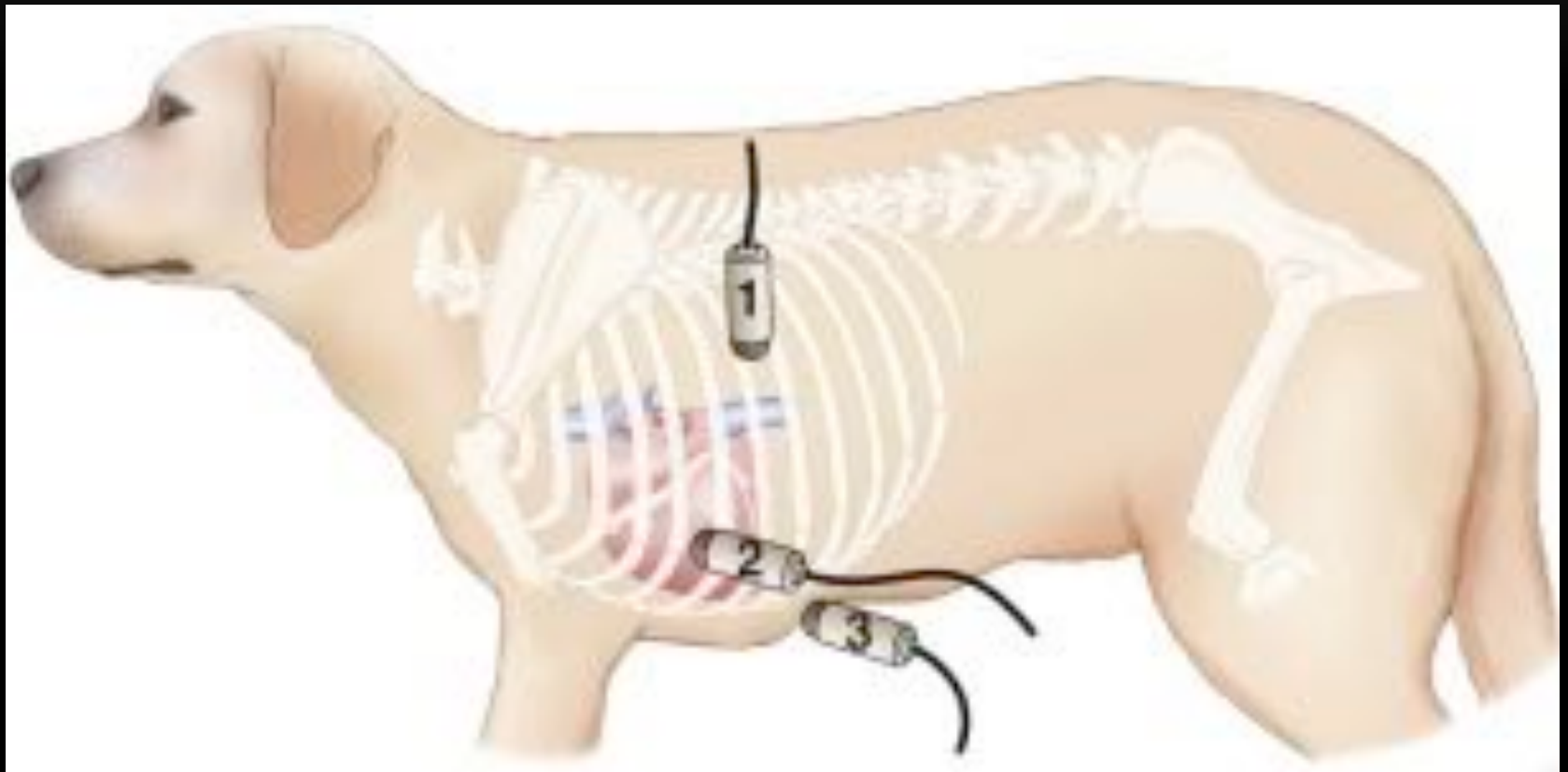FLUID EVALUATION

- “Permission to FAST, is permission to tap” -*G. Lisciandro*
- Collecting a fluid sample will help guide your diagnosis
 - Blood vs transudate vs septic effusion

TFAST

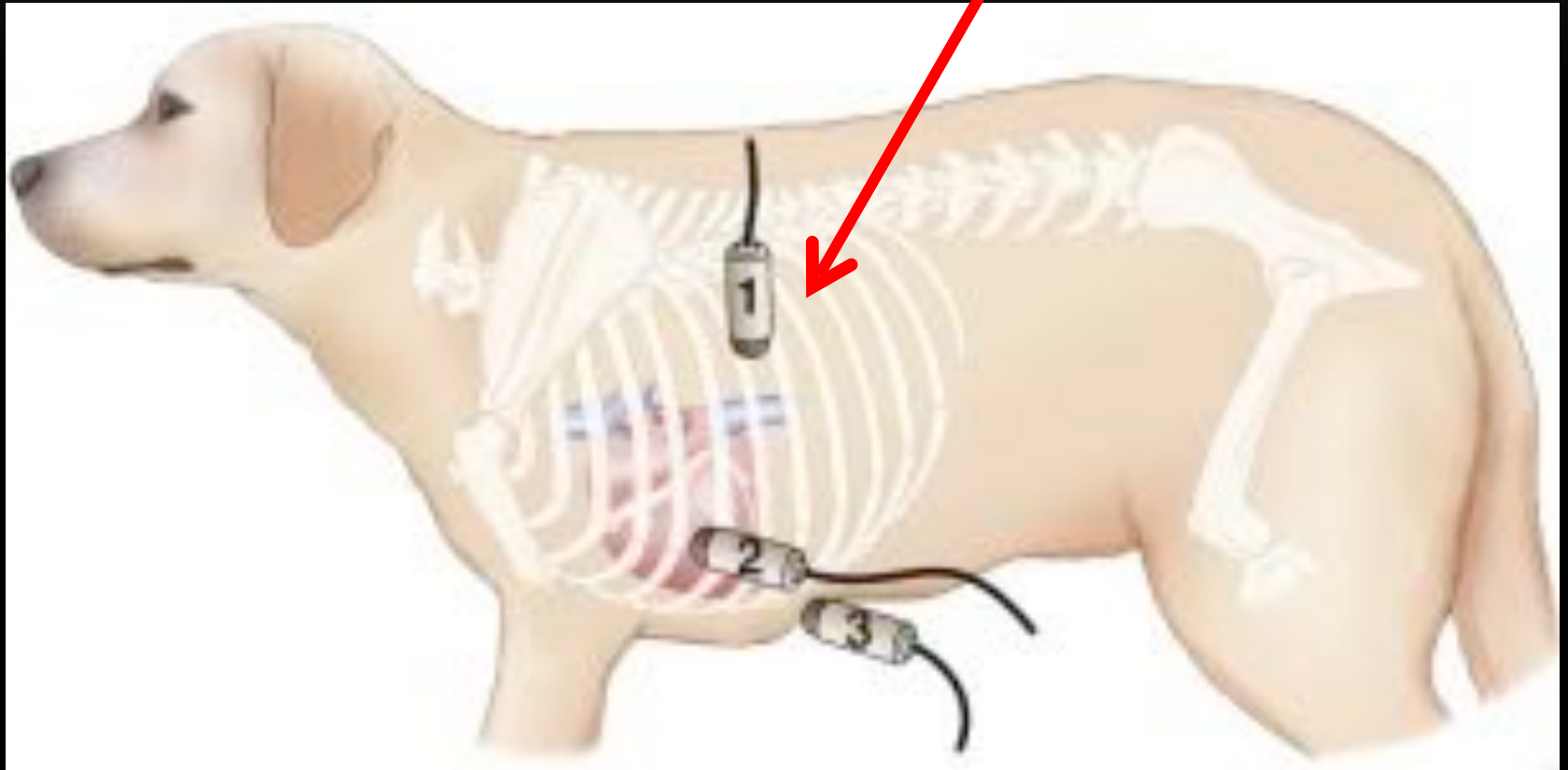
- 5 easy to obtain views
 - Left chest tube site
 - Left pericardial chest site
 - Right chest tube site
 - Right pericardial chest site
 - Subxiphoid view
- TFAST³
 - Trauma, triage and tracking (Lisciandro, 2011)

TFAST SITES



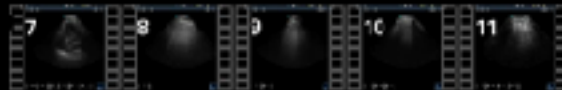
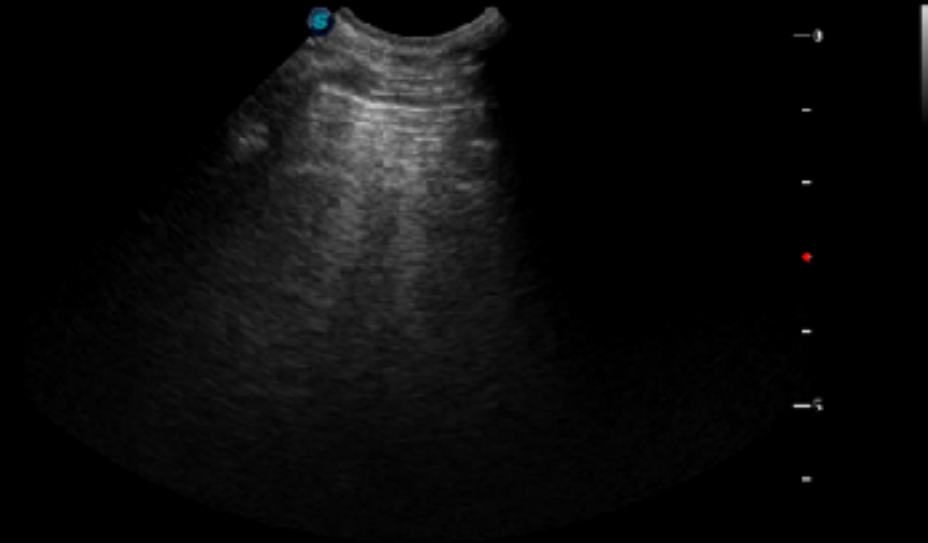
TFAST SITES

1- Longitudinal plane
perpendicular to ribs
7-9th ICS



SonoScape WVSBC C613/SmABD MI 0.9 TIS 0.3
20180503_094058 05/03/2018 09:49:55

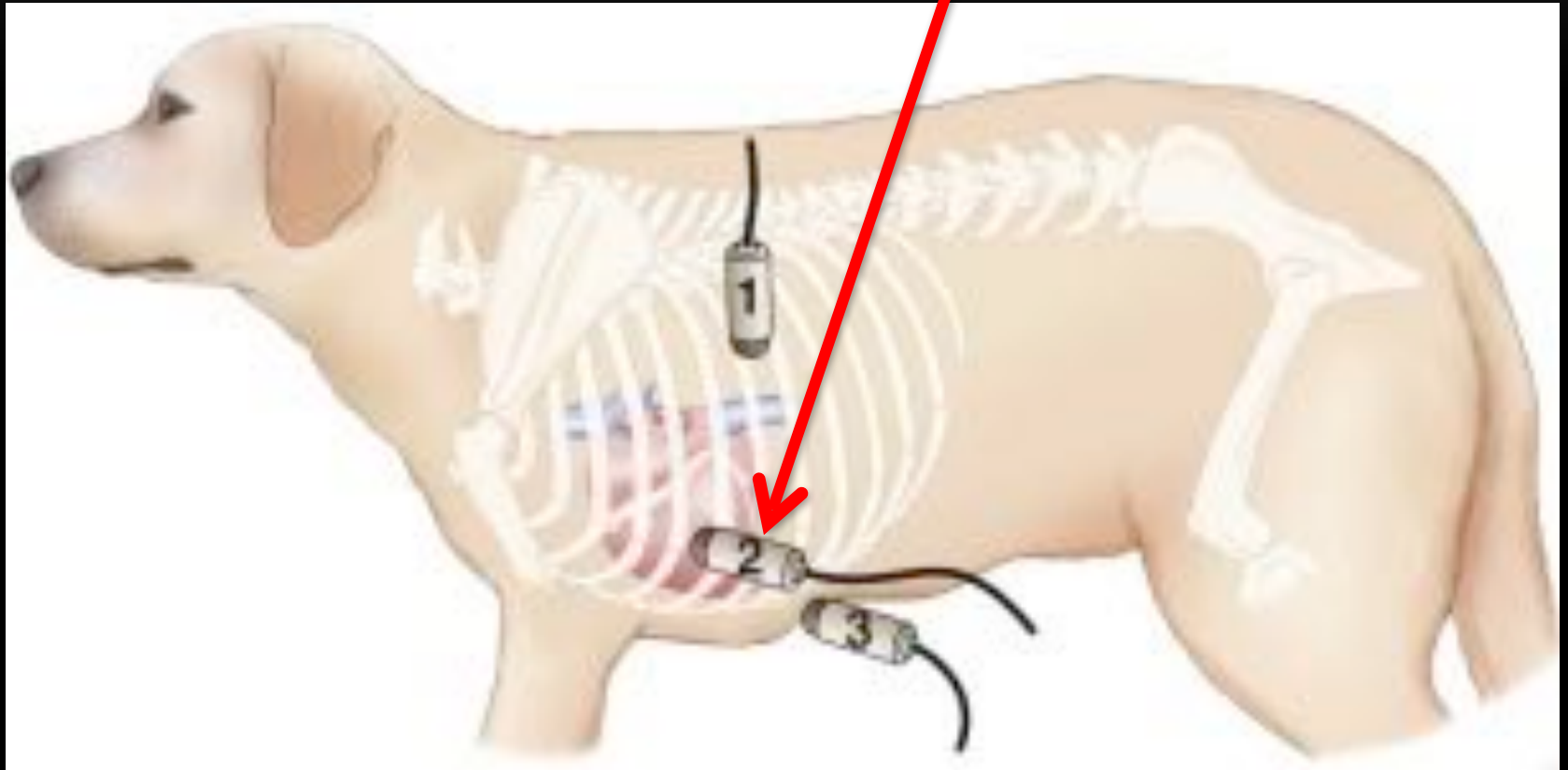
FPS 35
DIG 160/5
GN 52
I/P 6/10
PWR 85
FRQ 5.5-8.5
D 6.9cm



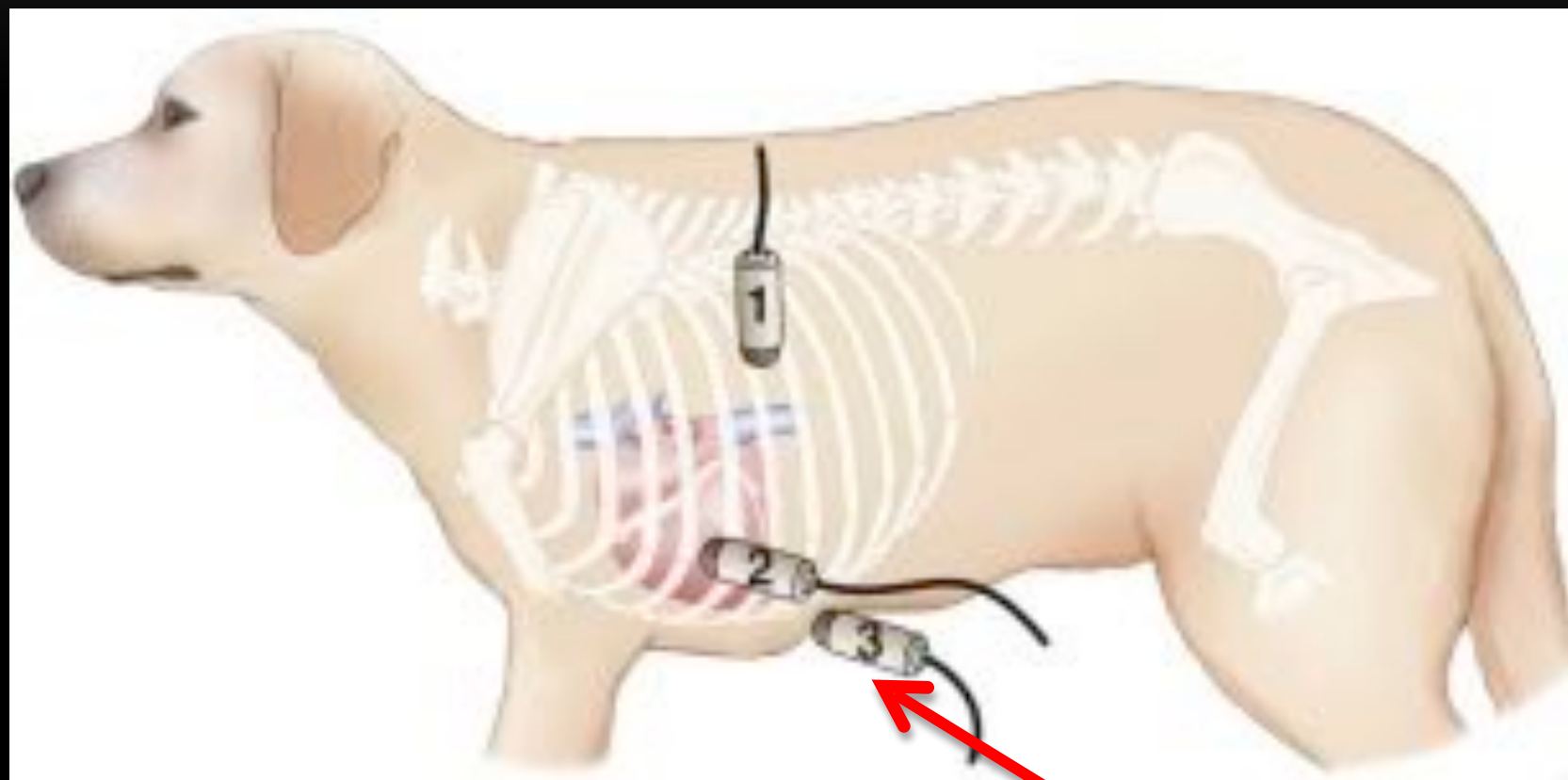
Video credit: M. Poirier, DVM

TFAST SITES

2-Longitudinal and transverse



TFAST SITES



3- Subxiphoid

SCOTT PEG, DAISY T37571 DOB: 05/08/2007 F TSU VET CARDIOLOGY 03/13/2010 11:22:41AM

LG DOG

X5-1

42Hz

19cm

2D

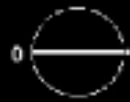70%

C 47

P Low

HGen

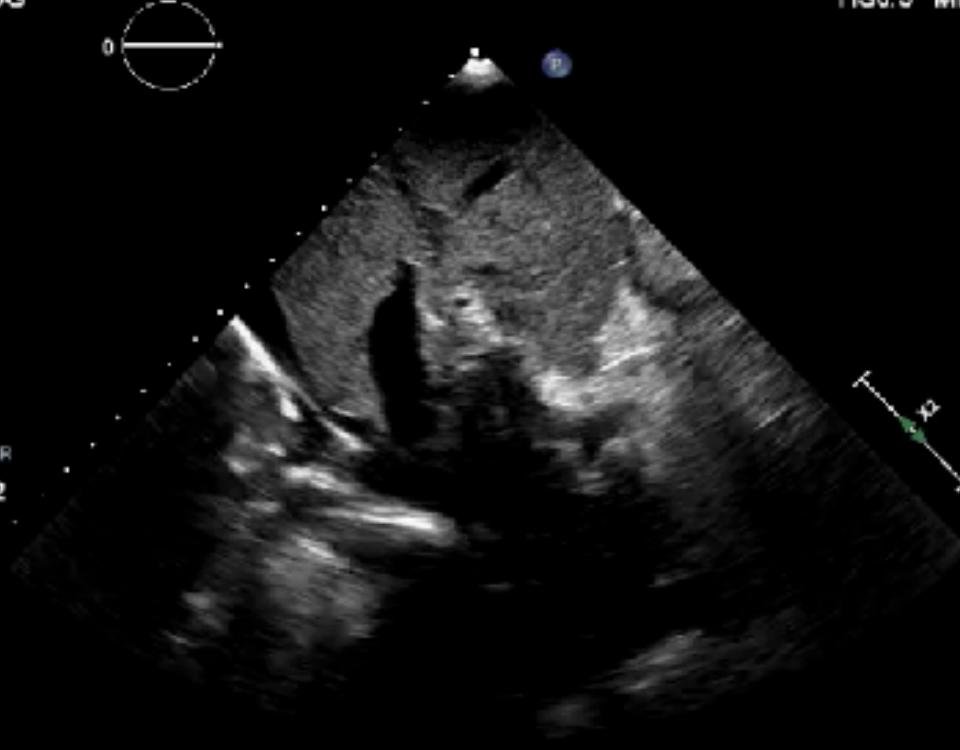TIS 0.5 MI 1.3



M4



③
P R
1.6 3.2



*** bpm

TFAST GOALS

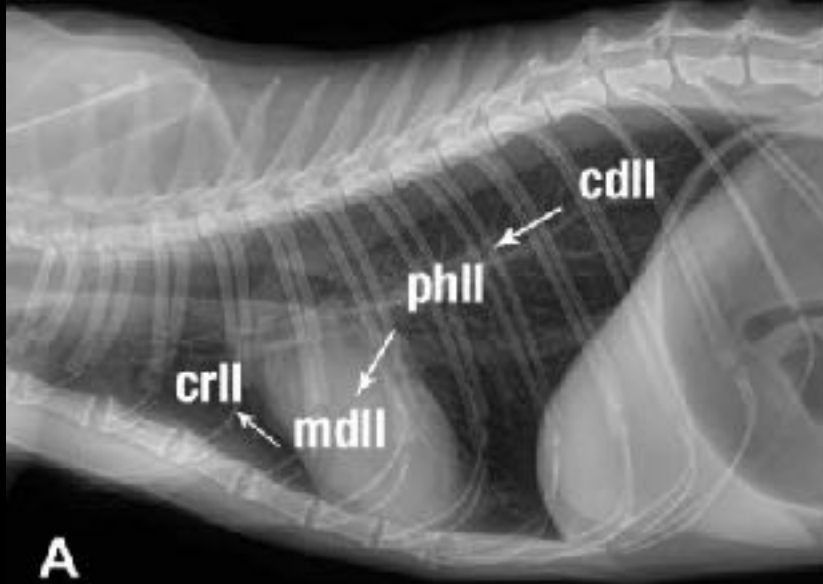
- Detection
 - Pericardial effusion
 - Pleural effusion (Vet BLUE)
 - Pneumothorax
- Respiratory distress case
 - Upper vs lower airway
 - Non-respiratory cause

POINT-OF-CARE LUNG ULTRASOUND

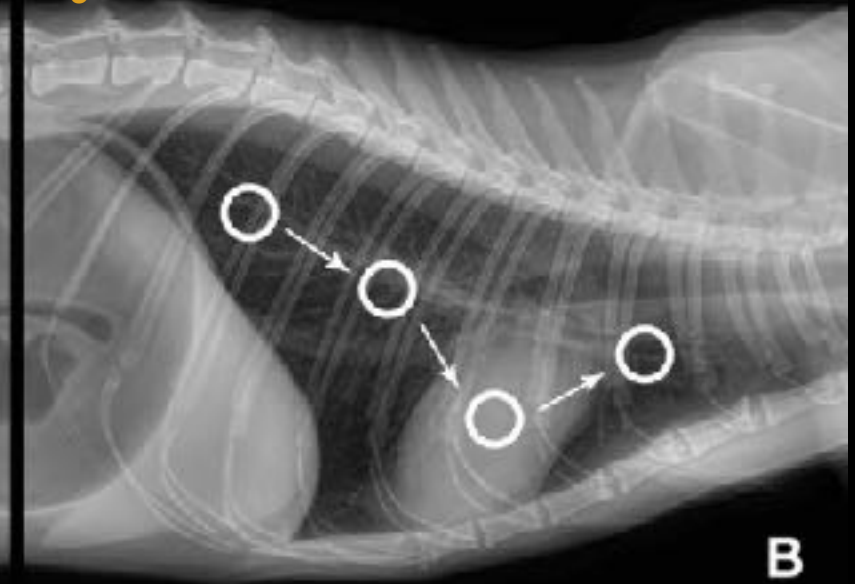
- Evaluate for presence of interstitial pulmonary edema (alveolar-interstitial syndrome)
 - B-lines
 - “Comet tails”
 - “Lung Rockets”
 - “Ring-down artifacts”
- Cardiogenic vs non-cardiogenic pulmonary edema
 - Sensitivity 84%, specificity 74% (Ward, Liscandro, 2018)

VET BLUE SITES

Left thorax



Right thorax



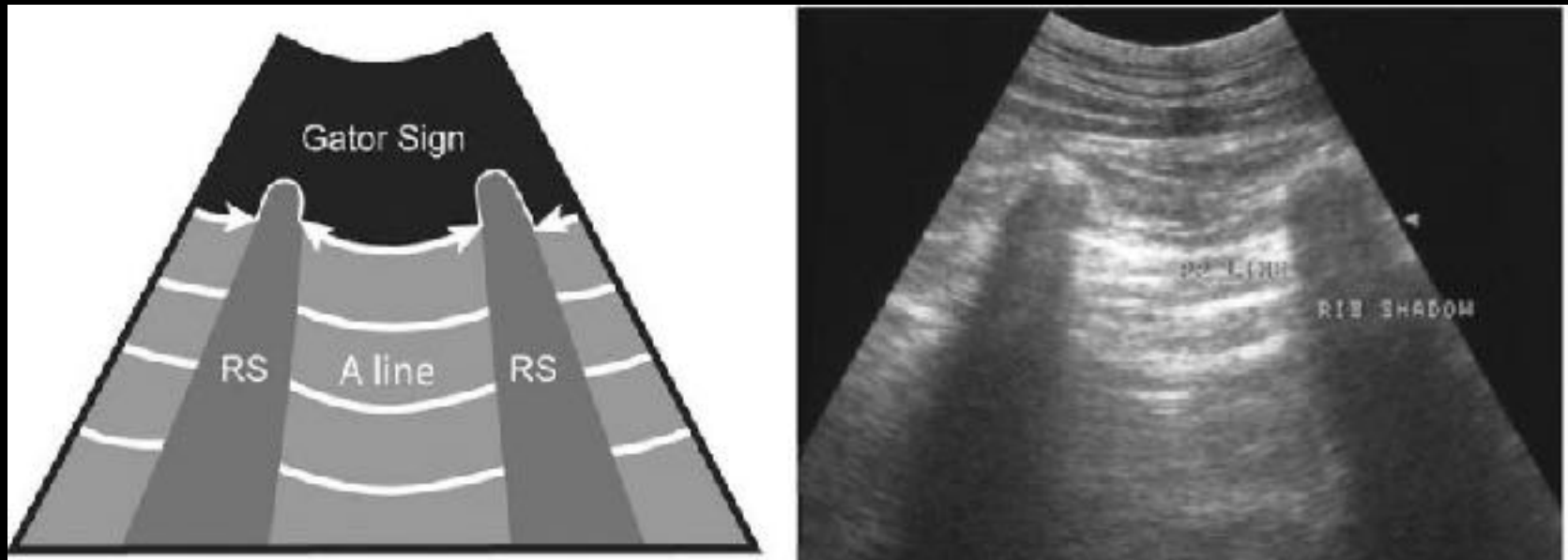
Lisciandro, 2018



DETECTION OF B LINES

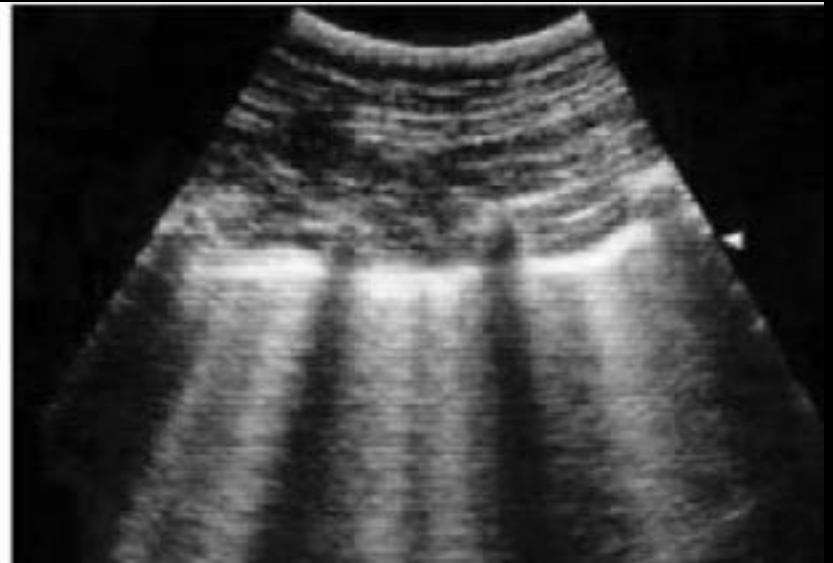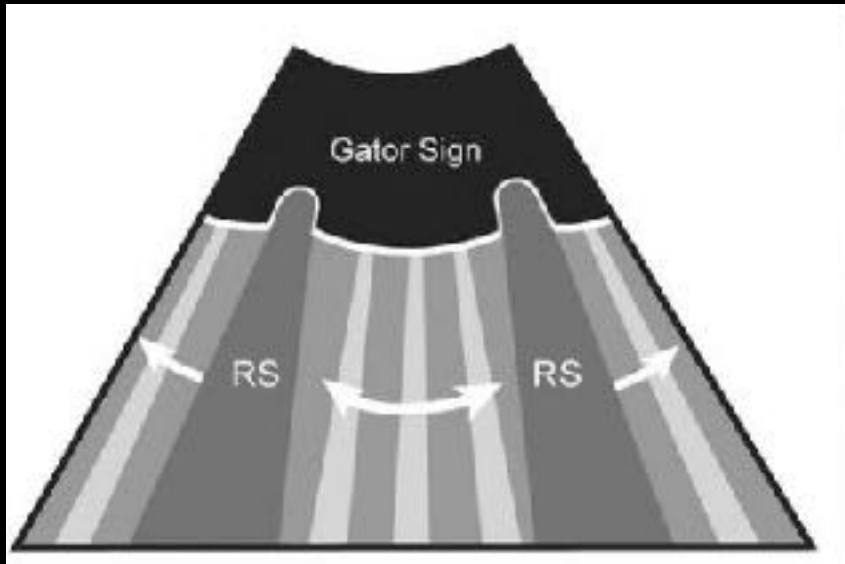
- Indicative of lung with water adjacent to air
 - 1-3mm of the surface of the lung
- Distribution can guide your diagnostic plan

NORMAL "DRY" LUNG

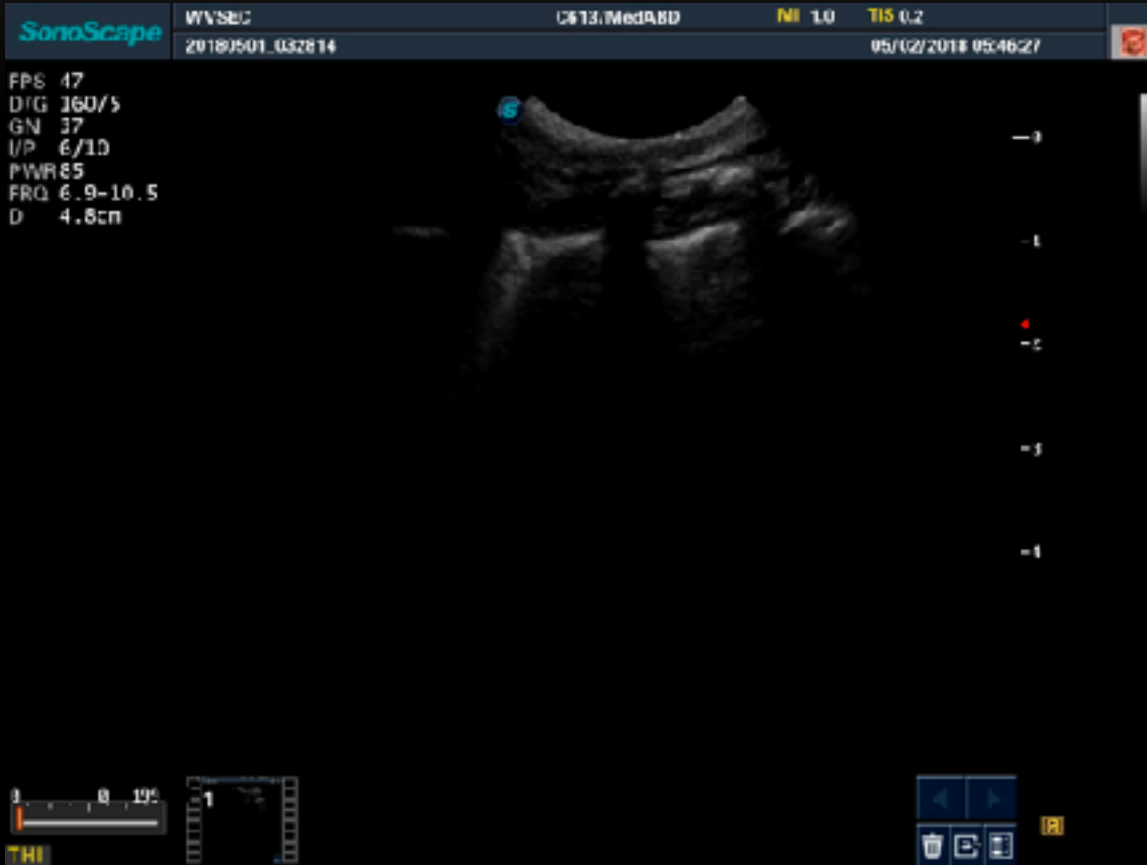

Lisciandro, 2014

PATHOLOGIC “WET” LUNG



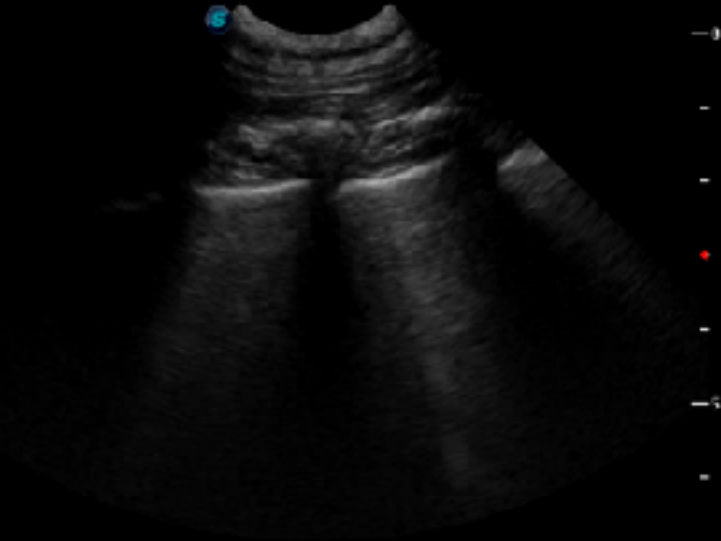Lisciandro, 2014



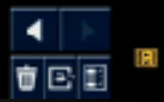
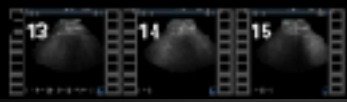
Video credit: M. Poirier, DVM

SonoScape WVSBC C613/SmABD MI 0.9 TIS 0.3
20180503_094058 05/03/2018 09:54:03

FPS 35
DIG 160/5
GN 52
I/P 6/10
PWR 85
FRQ 5.5-8.5
D 6.9cm



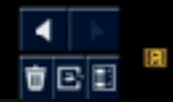
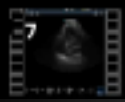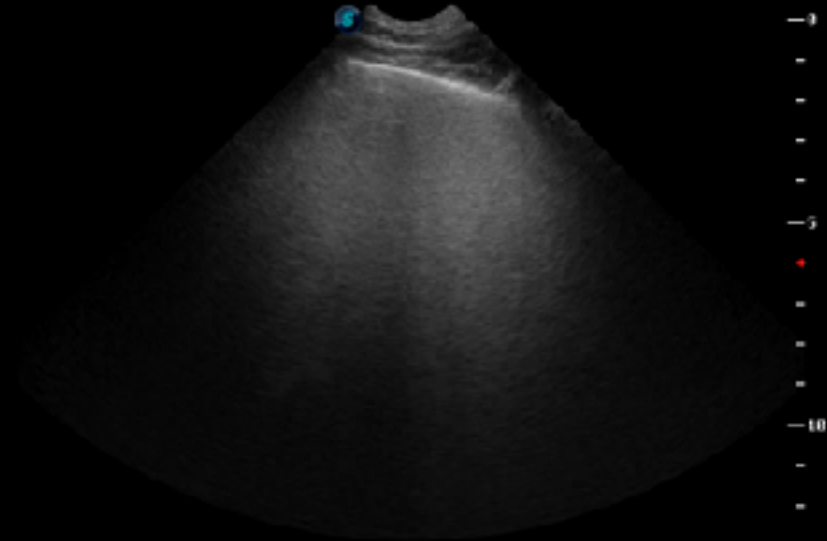
0 10 20
THI



Video credit: M. Poirier, DVM

SonoScape WVSBC C613/Sm ABD MI 0.6 TIS 0.2
20180503_094058 05/03/2018 09:46:23

FPS 21
DIG 160/5
GN 52
I/P 6/10
PWR 85
FRQ 5.5-8.5
D 12.9cm



Video credit: M. Poirier, DVM

CLINICAL IMPLICATIONS

Original Study

Journal of Veterinary Emergency and Critical Care 28(5) 2018, pp 415–428
doi: 10.1111/vec.12750

Distribution of alveolar-interstitial syndrome in dogs and cats with respiratory distress as assessed by lung ultrasound versus thoracic radiographs

Jessica L. Ward, DVM, DACVIM; Gregory R. Lisciandro, DVM, DACVECC and
Teresa C. DeFrancesco, DVM, DACVIM, DACVECC

CLINICAL IMPLICATIONS

- Helpful in your CHF cats, 40% of these cats will not have a murmur, arrhythmia (Smith, 2011)
- Ward et. al in 2017 found that >1 VetBLUE site strongly positive for B lines was 78.8% sensitive and 83.3% specific for diagnosis of CHF in feline and canines
 - Similar results to thoracic radiology without the risk
 - False positives: cannot differentiate other causes of interstitial or alveolar disease
 - Minimal change experienced vs inexperienced operator

FOCUSED CARDIAC ULTRASOUND

- Sites for abbreviated assessment
- 2D short axis right parasternal view (Md site in VetBLUE)



LA:A0 RATIO: LEFT ATRIUM TO AORTA

- LA:Ao normal 1:1
 - >1.3 canine suggest left side heart disease (Rishniw, 2000)
 - >1.6 feline suggest left side heart disease (Abbott, 2006)

SonoScape

WVSB: 20180503_094058

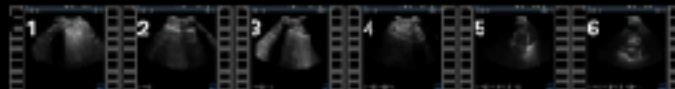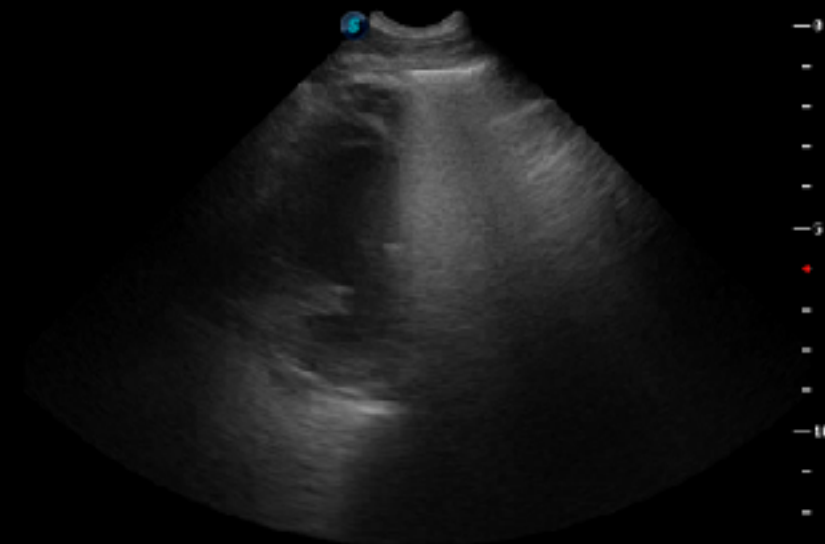
C613/SmABD

Mi 0.6

TIS 0.2

05/03/2018 09:45:44

FPS 21
DIG 160/5
GN 52
I/P 6/10
PWR 85
FRQ 5.5-8.5
D 12.9cm



Evaluation of point-of-care thoracic ultrasound and NT-proBNP for the diagnosis of congestive heart failure in cats with respiratory distress.

Ward JL¹, Lischiandro GR², Ware WA¹, Viall AK³, Aona BD⁴, Kurtz KA⁴, Reina-Doreste Y⁴, DeFrancesco TC⁴.

- Subjective vs objective assessment
 - LA:Ao >1.5, sensitive 93.9%, 94.4%

SUBJECTIVE CARDIAC CONTRACTILITY



CONCLUSION

- FAST ultrasound offers a large amount of information in a short amount of time
 - Can be performed with a novice operator with similar results
 - Is clinically applicable to many patients
 - Can offer another source of income to your practice
-

QUESTIONS?