What To Do When An Ocular Emergency Arises

Melissa A. Kubai, DVM, MS, DACVO
Assistant Professor of Ophthalmology
Iowa State University

Step 1

- Take a deep breath and keep calm…check!

Step 2: Brief Mental Review of Ocular Anatomy

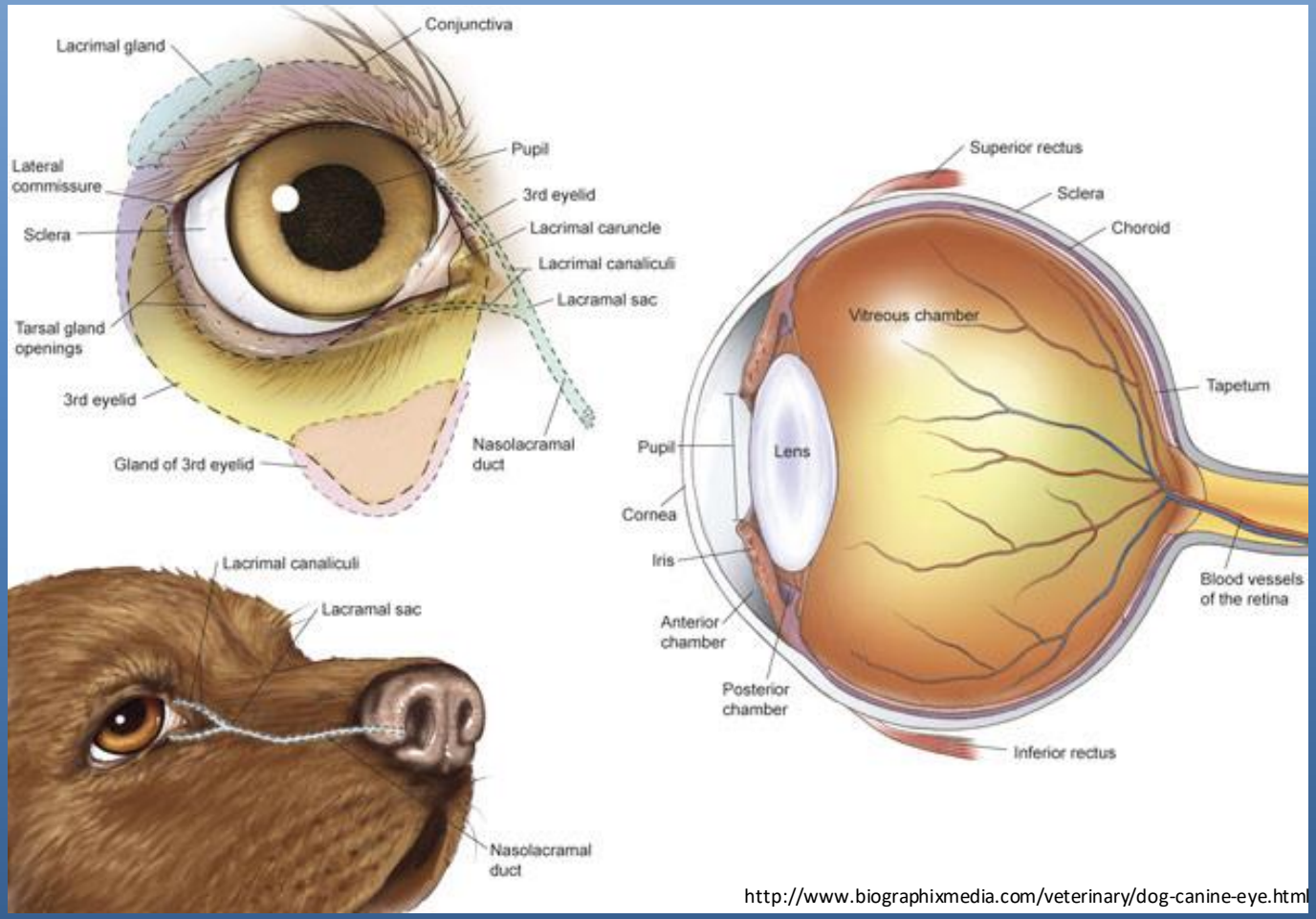

http://www.biographixmedia.com/veterinary/dog-canine-eye.html

Step 3: Assess the Patient

Step 3a: Assess Globe Size

- Enlarged (Buphthalmos)
- Displaced forward (Exophthalmos vs proptosis)
- Too small (Phthisical vs microphthalmos)
- Displaced inwards (Enophthalmos)

http://animaleyesofnj.com/client-info/common-eye-diseases/

http://davidwilliams.org.uk/

Step 3b: Assess Visual Status

- Present or absent menace response

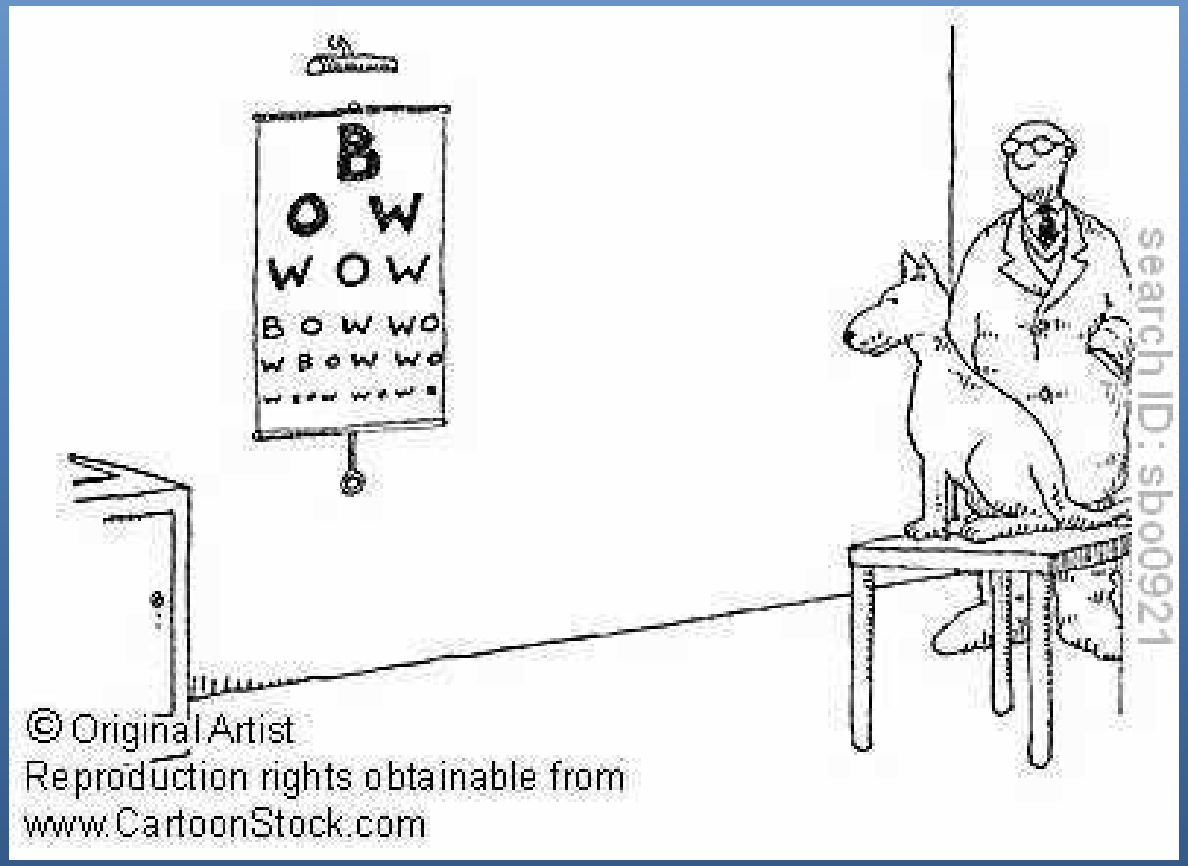

Step 3c: Assess Pupil Size

- Dilated (mydriatic)

- Constricted (miotic)

Step 3d: Assess for Corneal Edema

- Is there corneal cloudiness (edema)?
  - Is it focal or diffuse?
    - Focal → corneal ulceration, anterior lens luxation
    - Diffuse → intraocular disease (inflammation [uveitis] or elevated intraocular pressures [glaucoma]

Step 4: Perform Appropriate Diagnostic Tests

- Shirmer's Tear test (depending on the case)
- Fluorescein stain
- Tonometry (tonopen/tonovet)
- Corneal cytology +/- culture sensitivity

Step 5: Assess Inside of Eye

- Uveitis → present or absent
- Normal or abnormal lens position

What Conditions are 'True' Ocular Emergencies?

- Proptosis
- Anterior lens luxations
- Primary glaucoma
- Corneal perforations/lacerations
- Eyelid lacerations
- Infected corneal ulcers
- Corneal foreign bodies

Proptosis

- What should I do first?
- Assess patient
  - Is it a brachycephalic vs. dolichocephalic?
  - What should you look for if a dolichocephalic breed?
  - What is the visual status? Is there a direct or consensual PLR in the injured?

Proptosis

Proptosis

- What criteria are important for determining a successful globe replacement vs. need for enucleation?
  - Number of rectus muscles avulsed

Proptosis

Proptosis Repair

- Lateral canthotomy



Proptosis Repair

- Lubricate cornea and gently replace globe with scalpel handle or tongue depressor



Proptosis Repair

- Temporary Tarsorrhaphy
  - Continuous horizontal mattress pattern
  - Skin (partial thickness) & out MB Glands

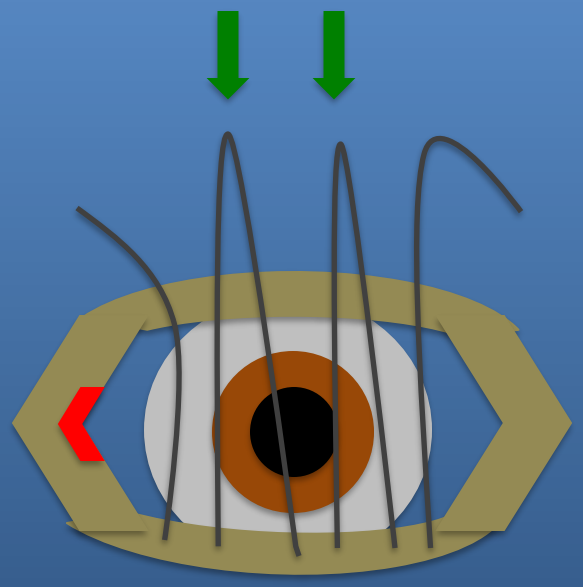

Temporary Tarsorrhaphy

- ± stents
- 4-0 or 5-0 non absorbable suture (Nylon, Silk, etc)
- Close the lateral canthotomy (we will talk about in eyelid laceration section)
- Leave the tarsorrhaphy in for 2-3 weeks
- Treat with topical antibiotic, systemic anti-inflammatory, pain meds

Anterior Lens Luxation

Anterior Lens Luxation

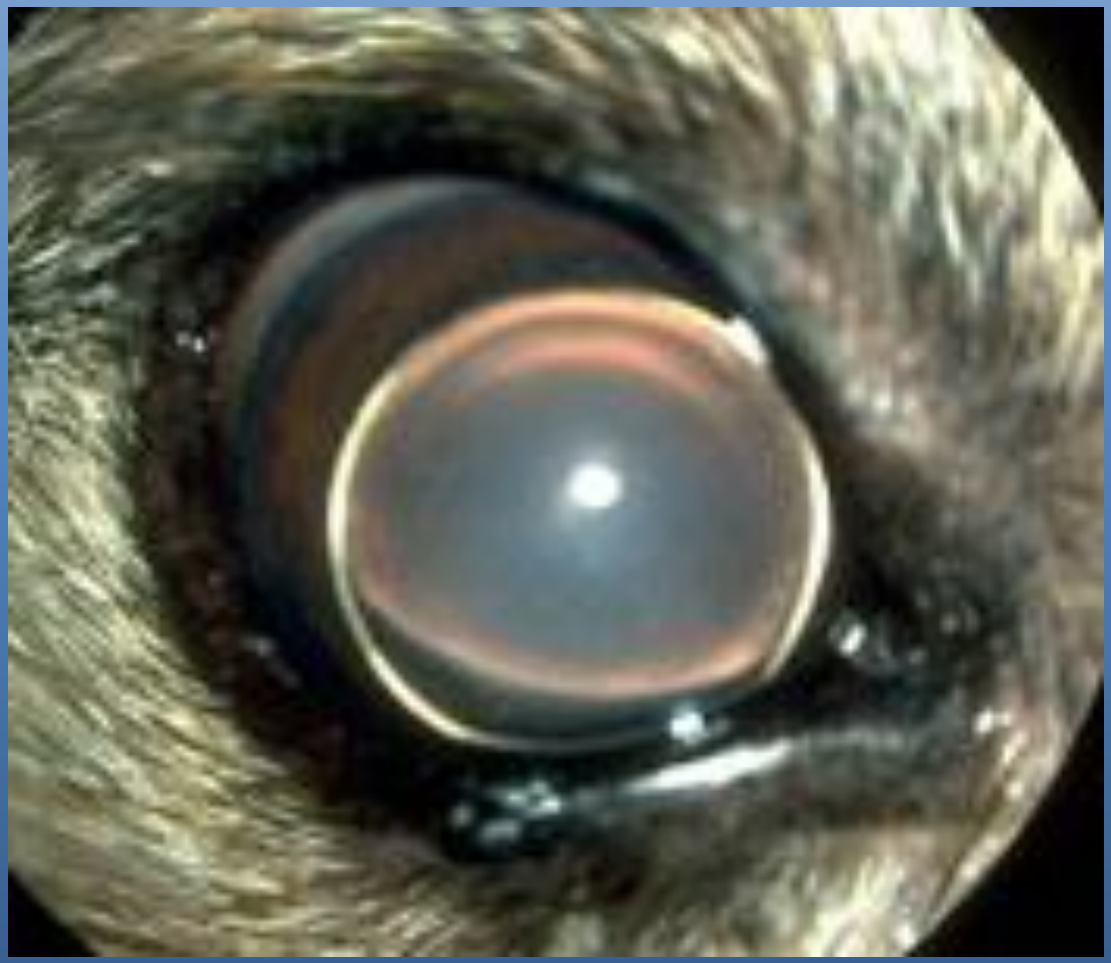

Anterior Lens Luxation

- What makes an anterior lens luxation an ocular emergency?
  - Acute glaucoma leading to blindness in 24 hrs
- How does anterior lens luxation → glaucoma?
  - Lens moves forward & brings vitreous forward into pupillary space → acts like a cork
    - IOP builds quickly as aqueous has no exit!!

Anterior Lens Luxation

- What should you do first in a case of anterior lens luxation?
  - Assess vision, dazzle, direct/consensual PLR
  - Determine if primary vs secondary lens luxation
    - Breed, age, ocular findings

Anterior Lens Luxation: Treatment Options

Visual Eye

- Lensectomy
- Couching Procedure

Non Visual Eye

- Couching Procedure
- Enucleation

Couching Procedure

- Heavy sedation with butorphanol IV
- Dog in dorsal recumbency
- Topical anesthesia and copious gonak gel
- Cotton tip applicator gentle pressure on the cornea moving dorsal to ventral
  - usually 2-3 times results in reposition of lens behind iris
  - Ensure lens in appropriate position
- Miotic (latanoprost)

Couching Procedure



Gentle pressure on cornea →dorsal to ventral

Primary Glaucoma

- What are the two forms?
- Open angle
  - Beagles, humans
- Closed angle
  - Basset hounds, Cocker spaniels, Shiba Inu, Northern breeds (Husky, Samoyed), Labs

Open Angle Glaucoma

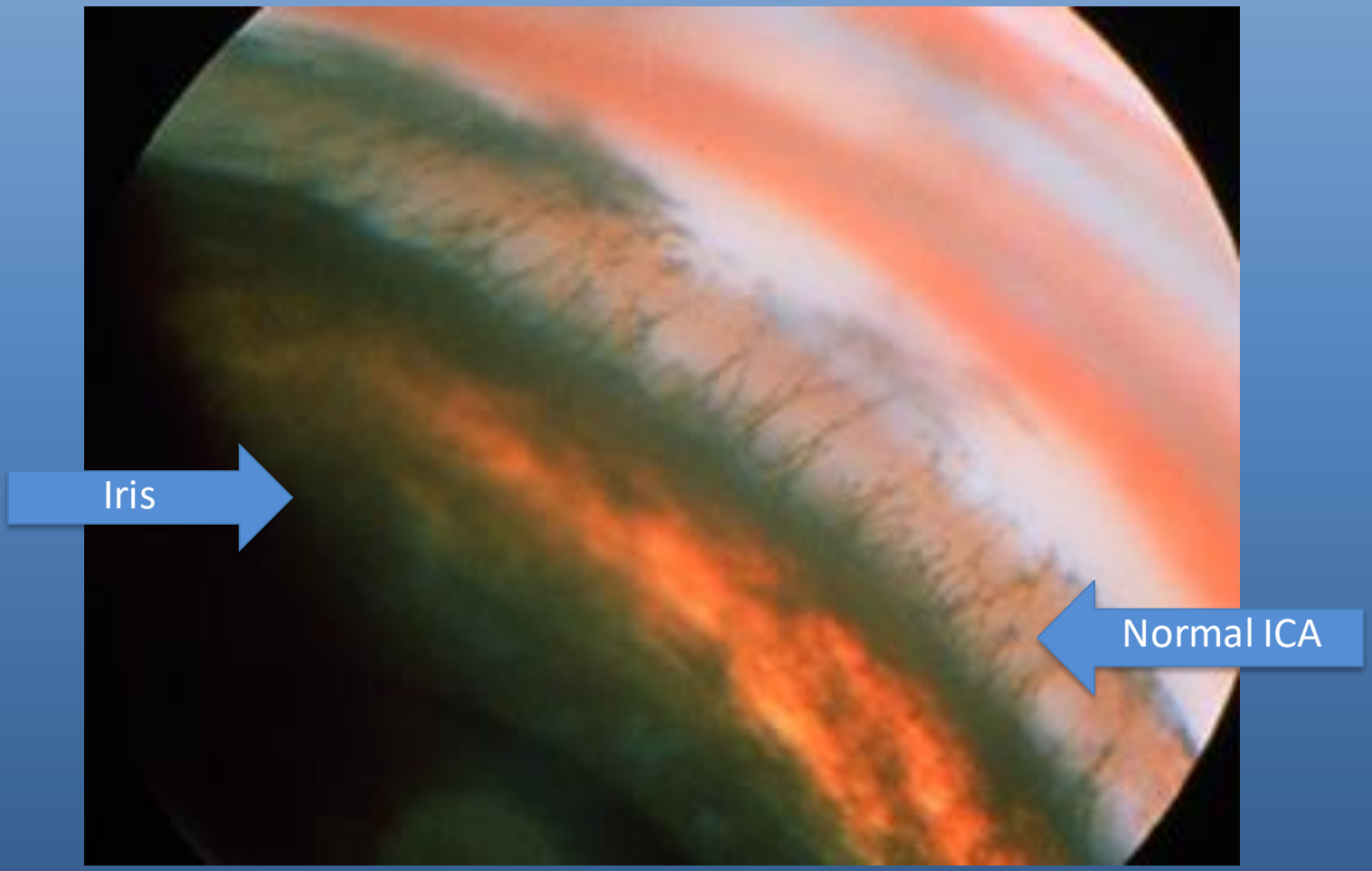

ICA = Iridocorneal angle

Closed Angle Glaucoma

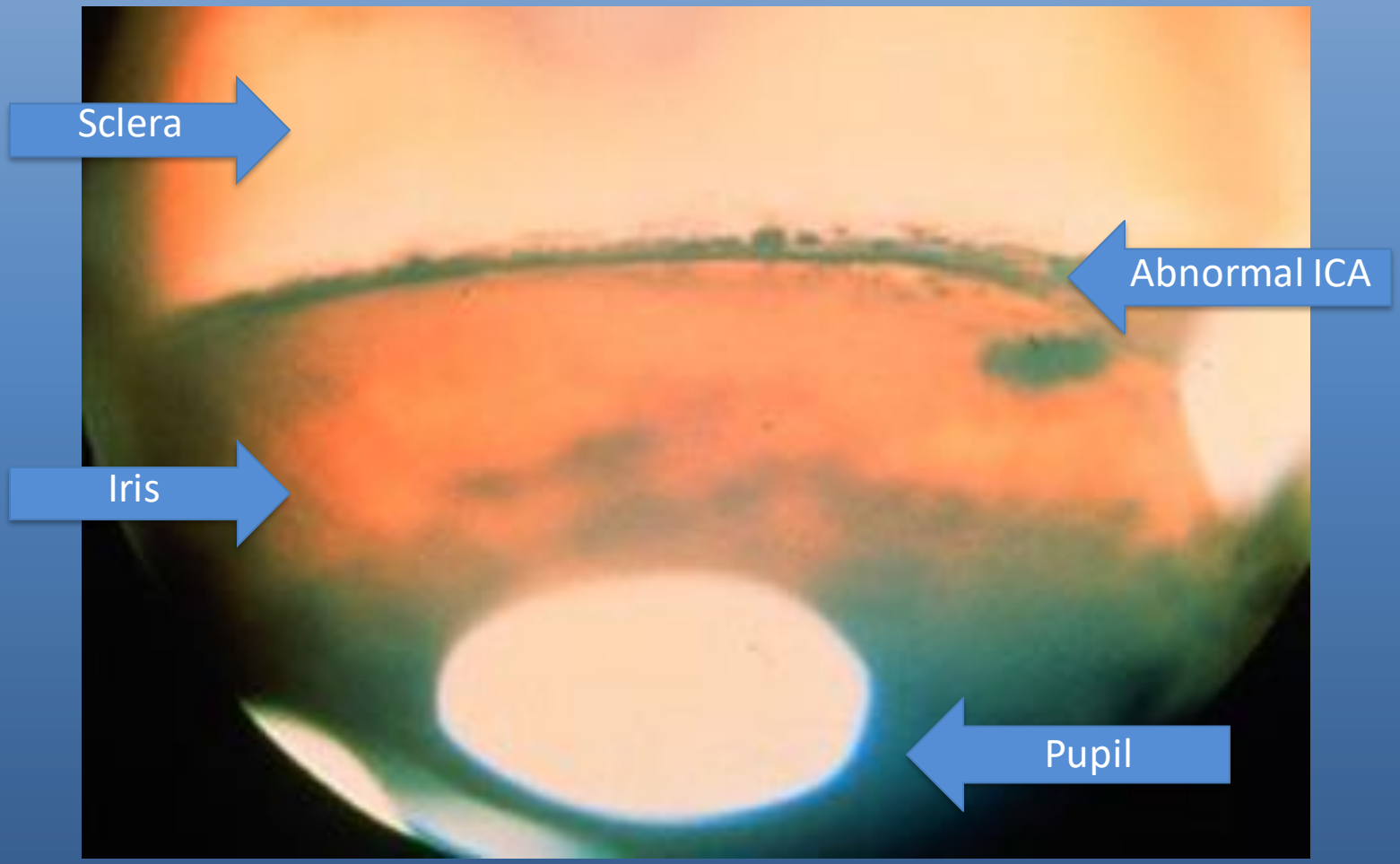

Primary Glaucoma

- How does primary glaucoma present in canines?
  - Diffuse corneal edema, mydriatic pupil, minimal to no flare, episcleral injection, blepharospasm, +/- menace, elevated IOP (usually between 50-70 mmHg)
  - Contralateral eye is completely normal

Primary Glaucoma

Primary Glaucoma: Treatment

- Affected eye
  - Instill alternating drops of Latanoprost and Cosopt (Dorzolamide/Timolol) q 5 minutes for 30 minutes
  - Recheck IOP → if still > 30 mmHg, then repeat alternating drops for another 30 minutes
    - If IOP <30 mmHg, can consider continuing combination latanoprost/cosopt -> response to medical management
    - If IOP >30 mmHg after 1 hr alternating drops → consider end stage surgical salvage procedure

Primary Glaucoma: Treatment

- Contralateral eye
  - Prophylactic therapy with Timolol 0.5% BID
    - Studies shown delayed onset of glaucoma on average about 26-30 months with prophylactic treatment

Corneal Perforation/Laceration

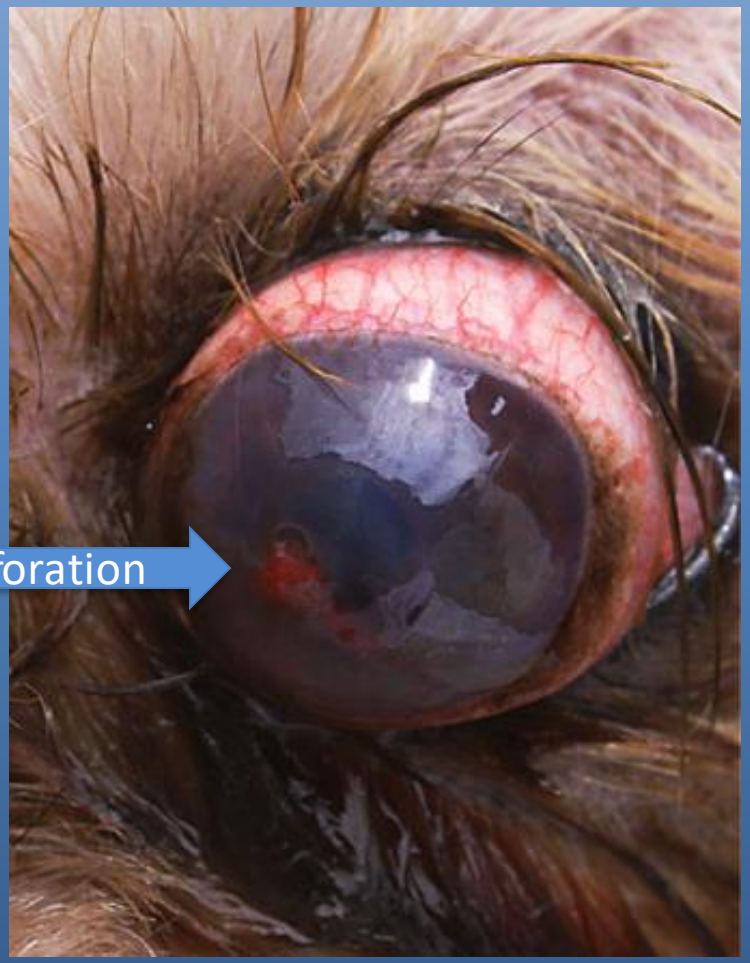

What else is abnormal?

Corneal Laceration/Perforation

- Keep dog calm as possible
- No pressure around the neck
- Avoid pre meds that can increase IOP like ketamine
- Avoid emetic inducing premeds like hydromorphone

What do I do next?

- Take a deep breath...
- Attempt to discern whether there is vision or positive prognosis for vision
  - Menace, dazzle and consensual PLR (affected eye drives contralateral pupil)
- Assess the size of the lesion and whether full thickness (regarding lacerations)
- Call your friendly ophthalmologist with results and potential need for surgery

Eyelid Laceration

Eyelid Laceration

- Thorough eye exam to ensure globe intact
  - Any corneal ulcers or trauma surrounding tissues
- Heavily sedate or short general anesthesia:
  - Clean the laceration site
    - Remove dirt or foreign debris
  - Freshen wound margins with a scalpel blade
  - Prepare for laceration repair

Eyelid Laceration

- Two Layer Closure
  - Subcutaneous
    - Absorbable suture → Vicryl (usually 5-0 or 6-0)
  - Eyelid margin and skin
    - Non absorbable suture → Nylon or Silk (usually 4-0 or 5-0)

Eyelid Laceration

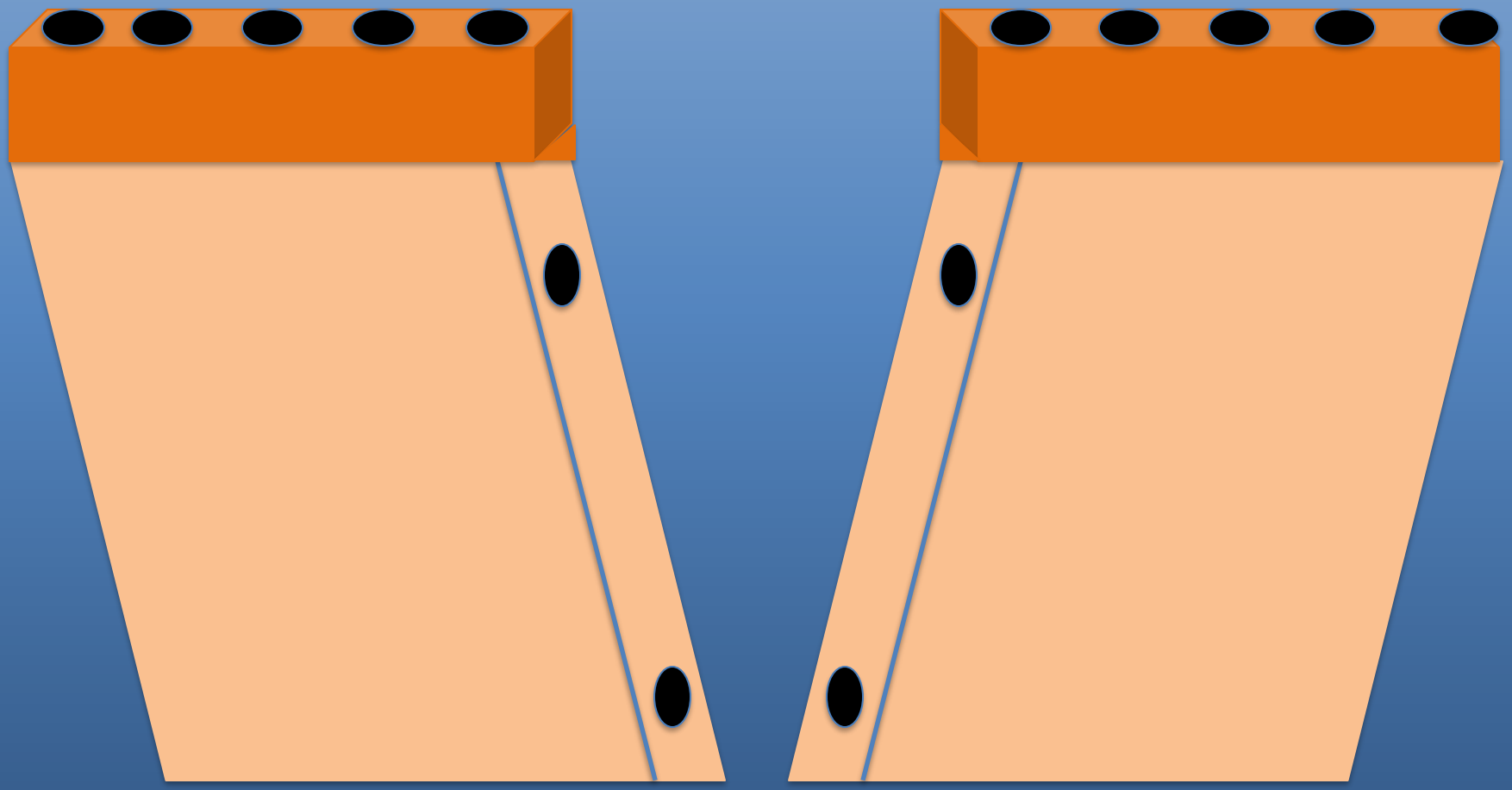

Subcutaneous Closure

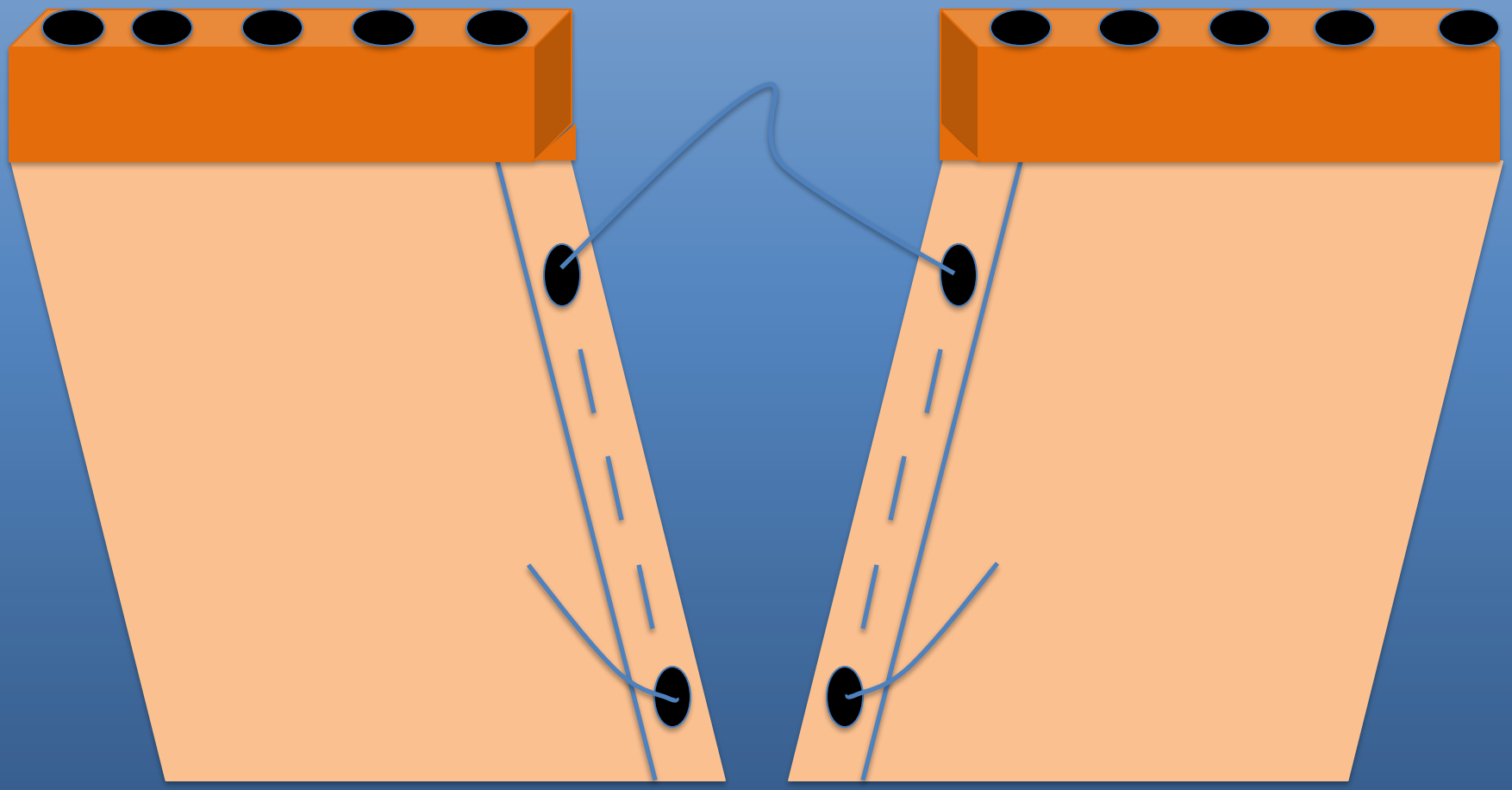

Figure 8 (Cruciate) Pattern

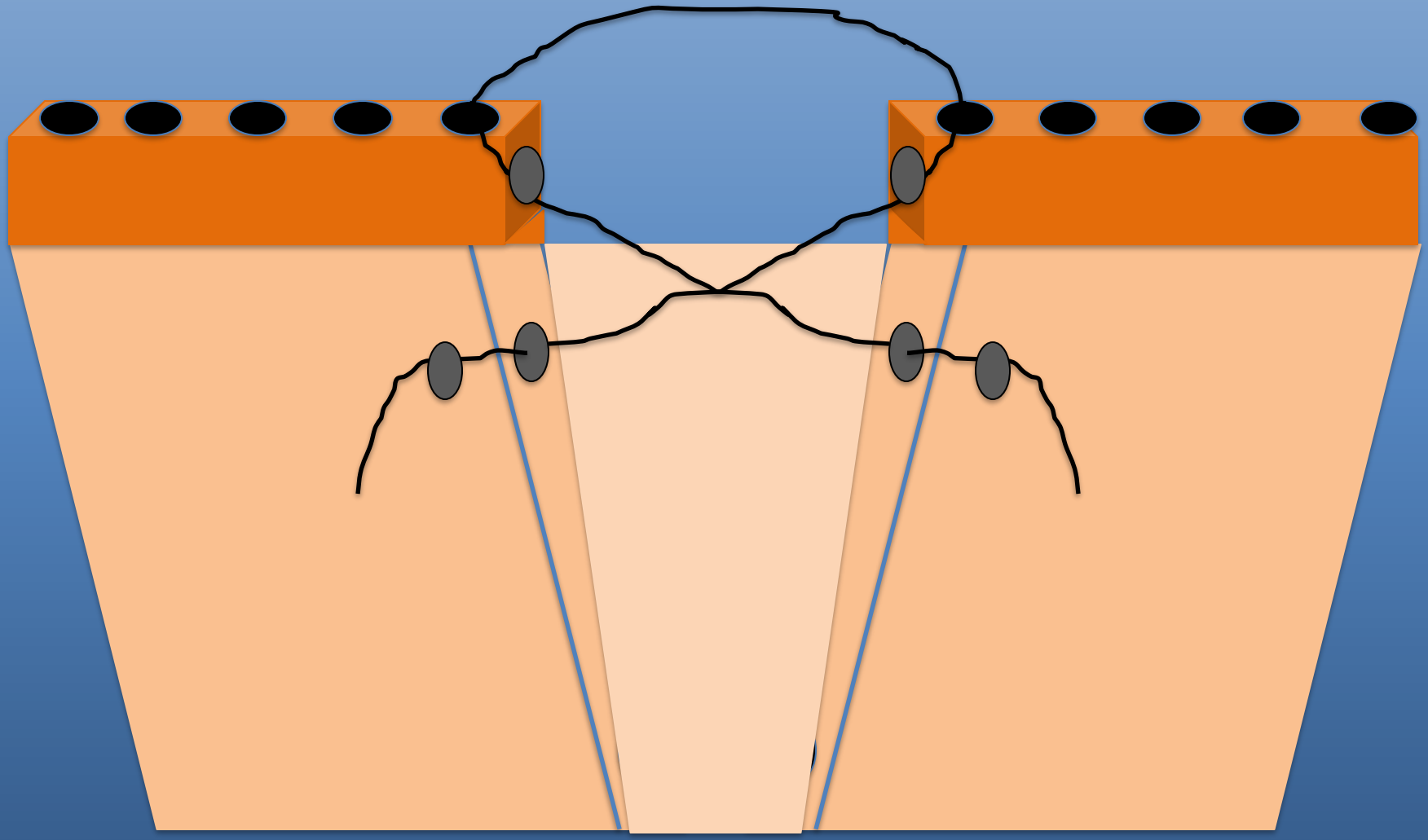

Simple Interrupted Closure

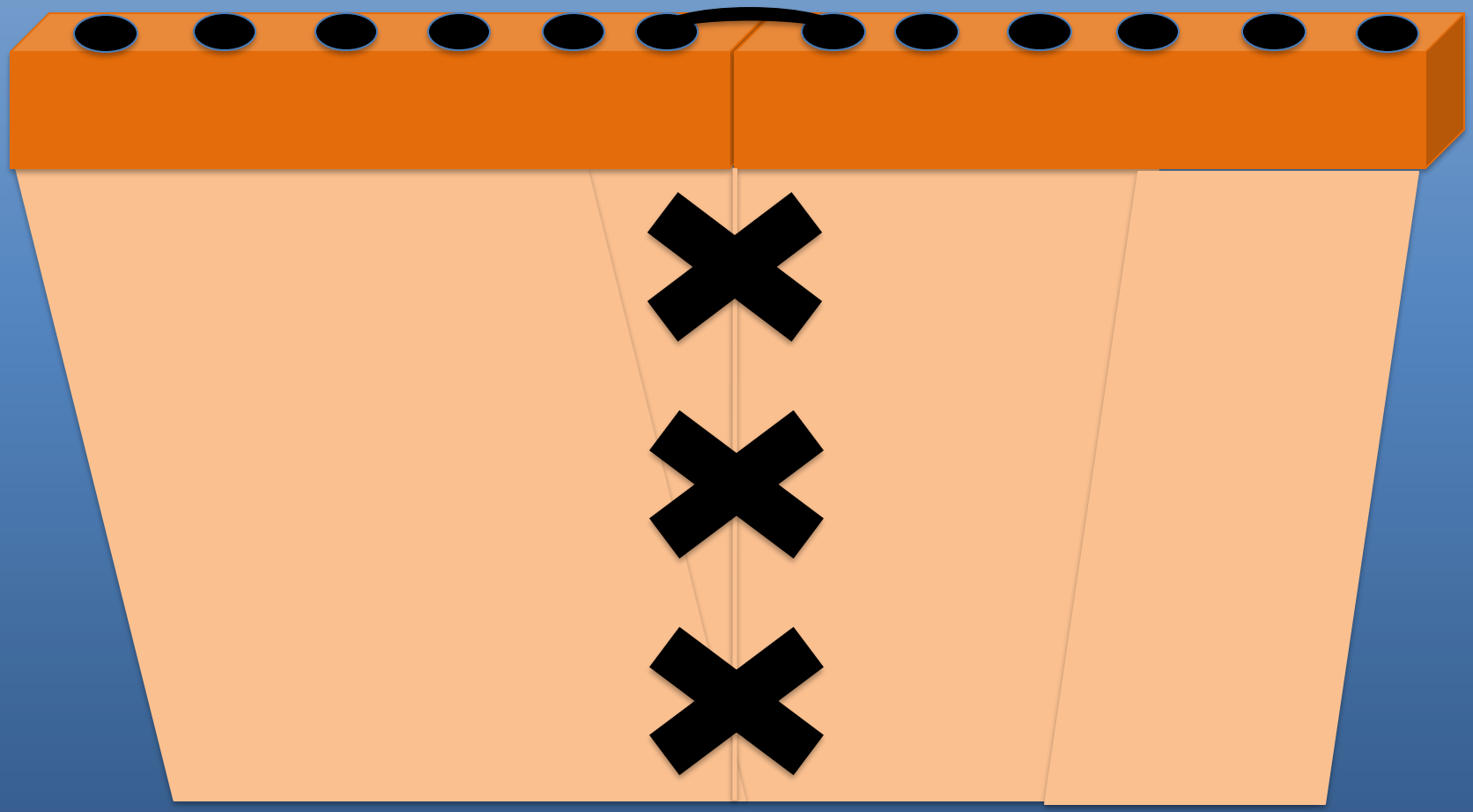

Important Points to Remember!

- Good apposition is KEY…not happy…do it again
- Why?
  - Eyelids essential for corneal health
    - Protection
    - Tear film distribution
    - Removal of debris (windshield wipers for eye)

What Happens with Incorrect Apposition?

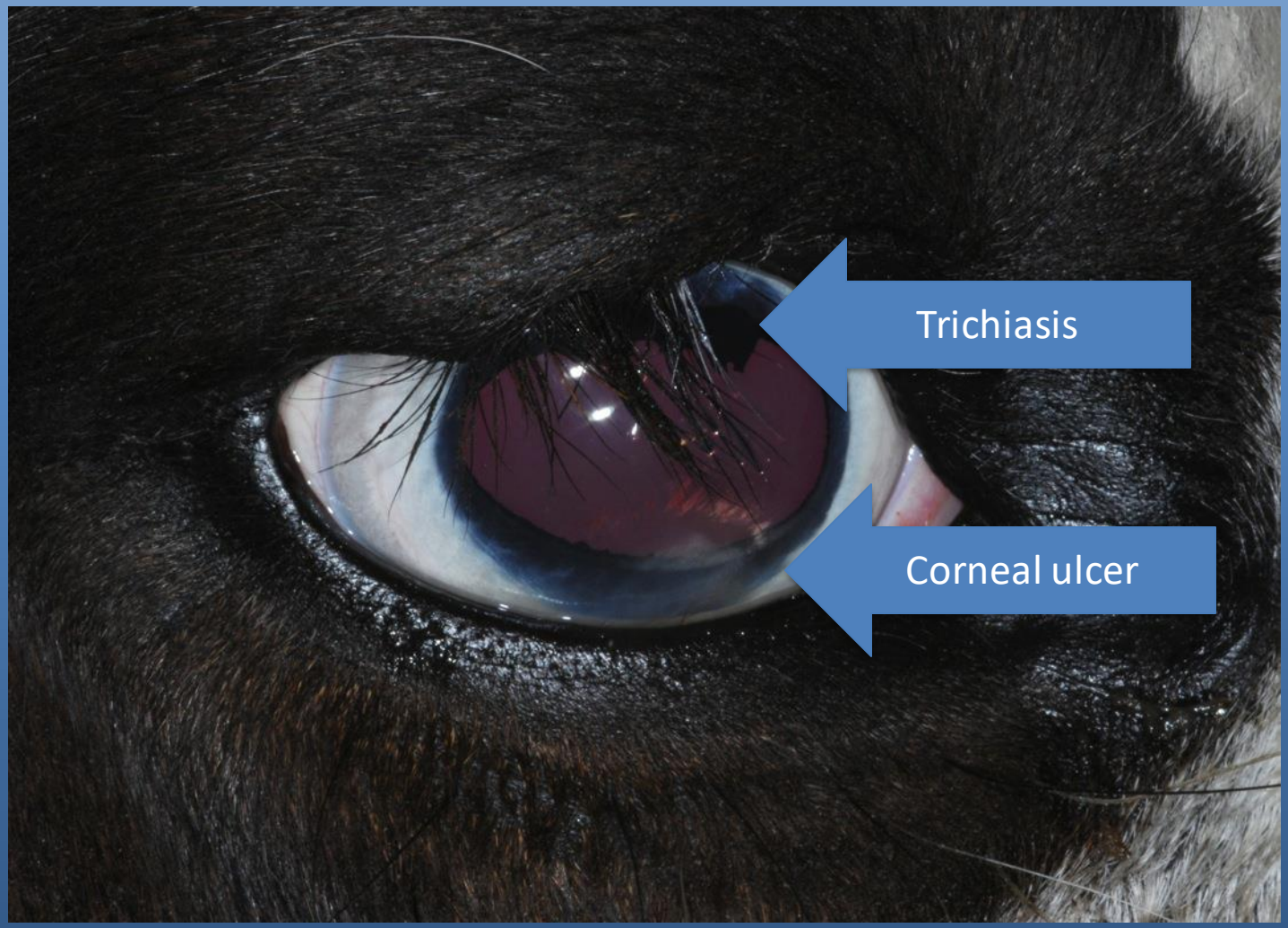

Reminders

- Tighten down 'Figure 8' suture snug
  - Always use surgeon knot first
  - Do not want the suture to significantly loosen as inflammation resolves
- Incorporate Figure 8 sutures into the next simple interrupted sutures
  - Keep suture away from cornea
- Protect your work → E collar! ☺

Eyelid Laceration Repair

Before

After

Post Op Care

- Topical broad spectrum antibiotic
  - NeoPolyBac ointment TID
- Systemic anti-inflammatories
  - NSAID (rimadyl, deramaxx, etc) x 7-10 days
  - Steroid (tapering anti-inflammatory dose) over 2-3 weeks
- Systemic antibiotic
  - Cephalexin 22 mg/kg PO BID or Clavamox 13.75 mg/kg PO BID x 14 days

Infected Corneal Ulcers

- Malacic Cornea → margins have a melting appearance (snot-like appearance on the cornea that does not remove with CTA)
- Corneal stromal involvement

What Causes Corneal Malacia (Aka Melting)?

- Proteinases → Collagenase and Gelatinase
  - Bacteria
    - Gram positive: Staph and Streptococcus spp.
    - Gram negative: Pseudomonas
  - Neutrophils
    - Neutrophil elastase (most common serine proteinase)
  - Cornea
    - Matrix metalloproteinases (MMP 2 and 9)

What Medications Can Help to Cease Corneal Malacia?

- Autologous serum/plasma
  - Alpha 2 macroglobulins & Alpha 1 anti-trypsin
    - MMP and serine proteinase inhibitor
- 1% Disodium ethylene-diaminetetra-acetic acid (EDTA)
  - Chelates Ca & Zn
    - MMP inhibitor
- Tetracyclines 0.1%
  - Chelates Ca & Zn
    - MMP inhibitor
- N-Acetylcysteine 5-10%
  - Chelates Ca & Zn
    - MMP inhibitor

Infected Corneal Ulcer: What To Do Next?

- Obtain and submit aerobic culture/sensitivity
  - Location of sampling?
- Corneal cytology
  - Blunt edge of scapel blade
  - Cytobrush (Microbrush international)
  - Kimura spatula

Treatment of Infected Corneal Ulcers

- Broad spectrum antibiotic
  - Based on corneal cytology
- Serum
  - Blood in a red top tube
  - Allow blood to clot for 10 minutes
  - Centrifuge for 10 minutes
  - Sterile removal of serum into 1 cc tuberculin syringe (remove needle and use syringe as dropper)
  - Keep refrigerated and discard after 5 days
- Atropine
- Systemic anti-inflammatory/oral pain medication
- +/- oral antibiotic (if corneal vessels present)

Treatment of Infected Corneal Ulcers

- Serum
  - Administer every 1-2 hours initially
- Broad spectrum antibiotic
  - Administer every 2-4 hours initially
- Atropine
  - Administer every 8-12 hours if severe reflex uveitis and no evidence of secondary glaucoma
- Tramadol PO every 8-12 hrs PRN & NSAIDs PO
- Recheck in 24-48 hours

Treatment of Infected Corneal Ulcer

- If > 50 % stromal loss
  - Conjunctival flap placement (Gold standard)

Color Atlas of Canine and Feline Ophthalmology, 2004
2004

Corneal Foreign Body

Corneal Foreign Body (Cactus Spine, Thorn, Seed Hull)

- Evaluate the periocular region
- Discern if foreign body is cornea, conjunctiva etc.
- If Superficial → Hydropulsion (squirt gun method)
- If Full Thickness → DO NOT PULL OUT!!
  - Call ophthalmology for evaluation and potential surgery

Post Op Care

Superficial/Deep Corneal Foreign Body

- Broad spectrum topical antibiotics
  - Ofloxacin, Ciprofloxacin
- Serum/plasma
- Atropine drops or ointment
  - Intraocular pain control
- Oral pain medications
  - Tramadol, NSAID, Gabapentin, etc.
- Oral antibiotics (if deep or penetrating)
  - Clavamox, Cephalexin, etc.
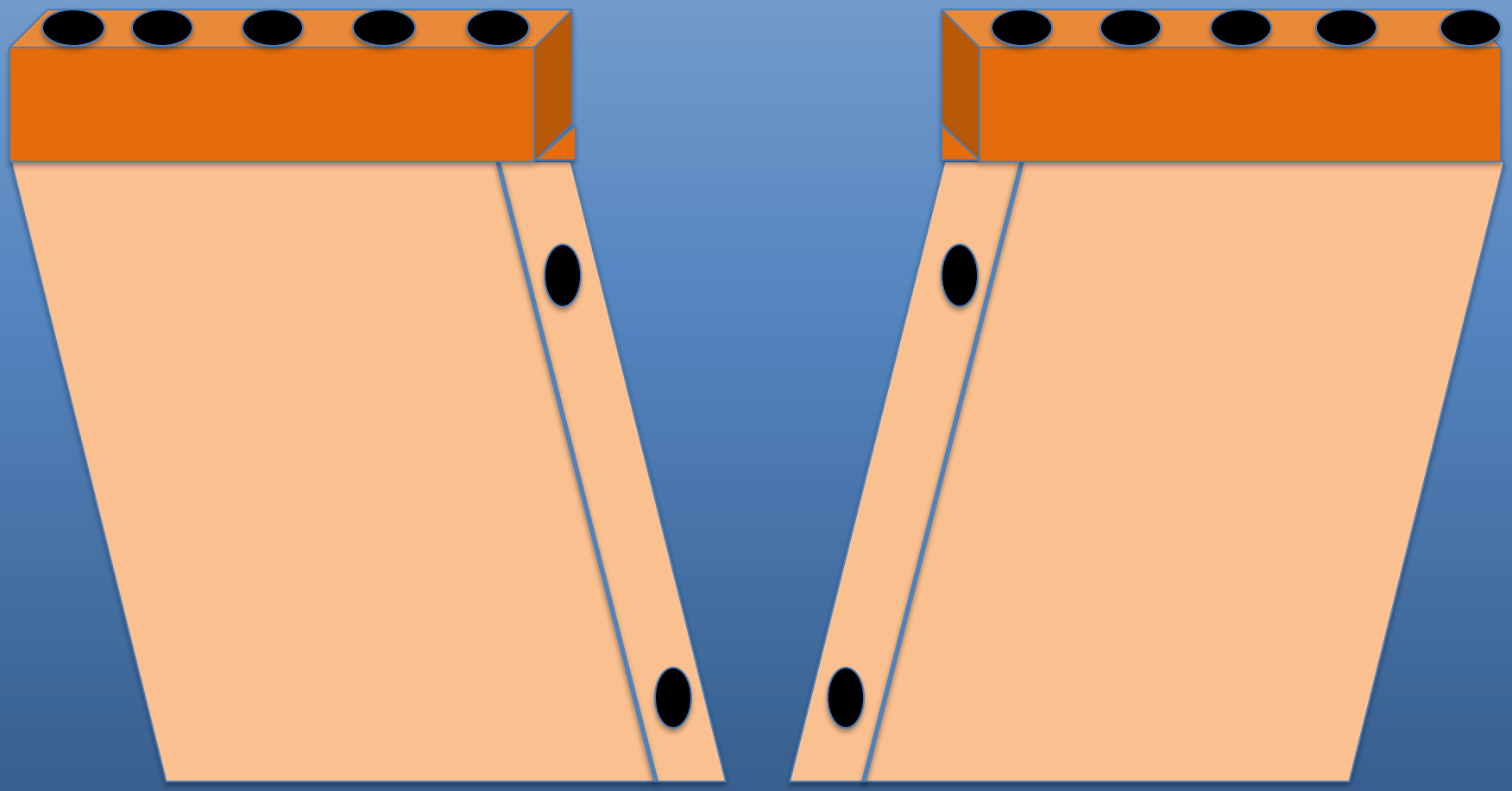
Questions?